

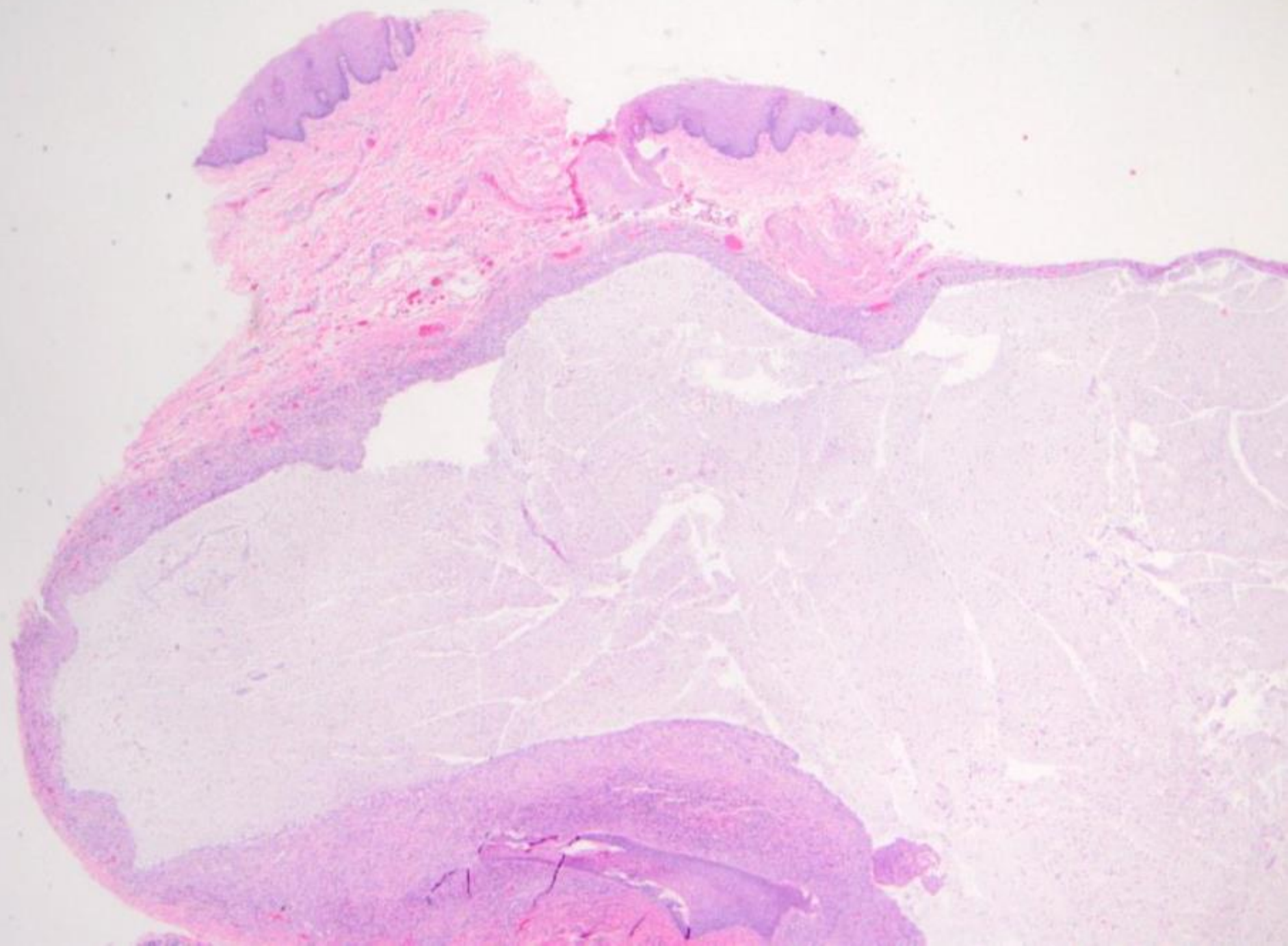
Oral Histopathology

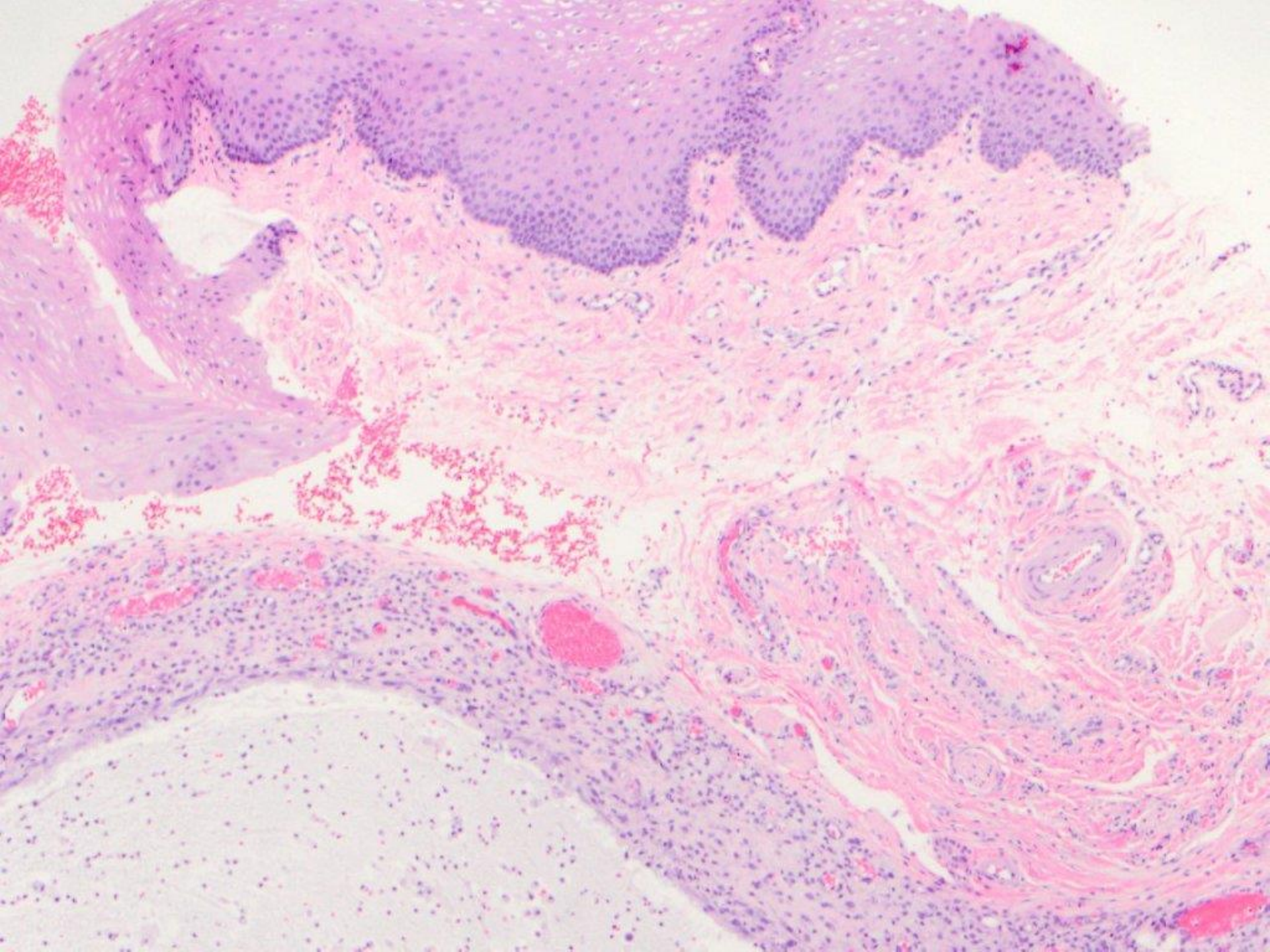
Series 16

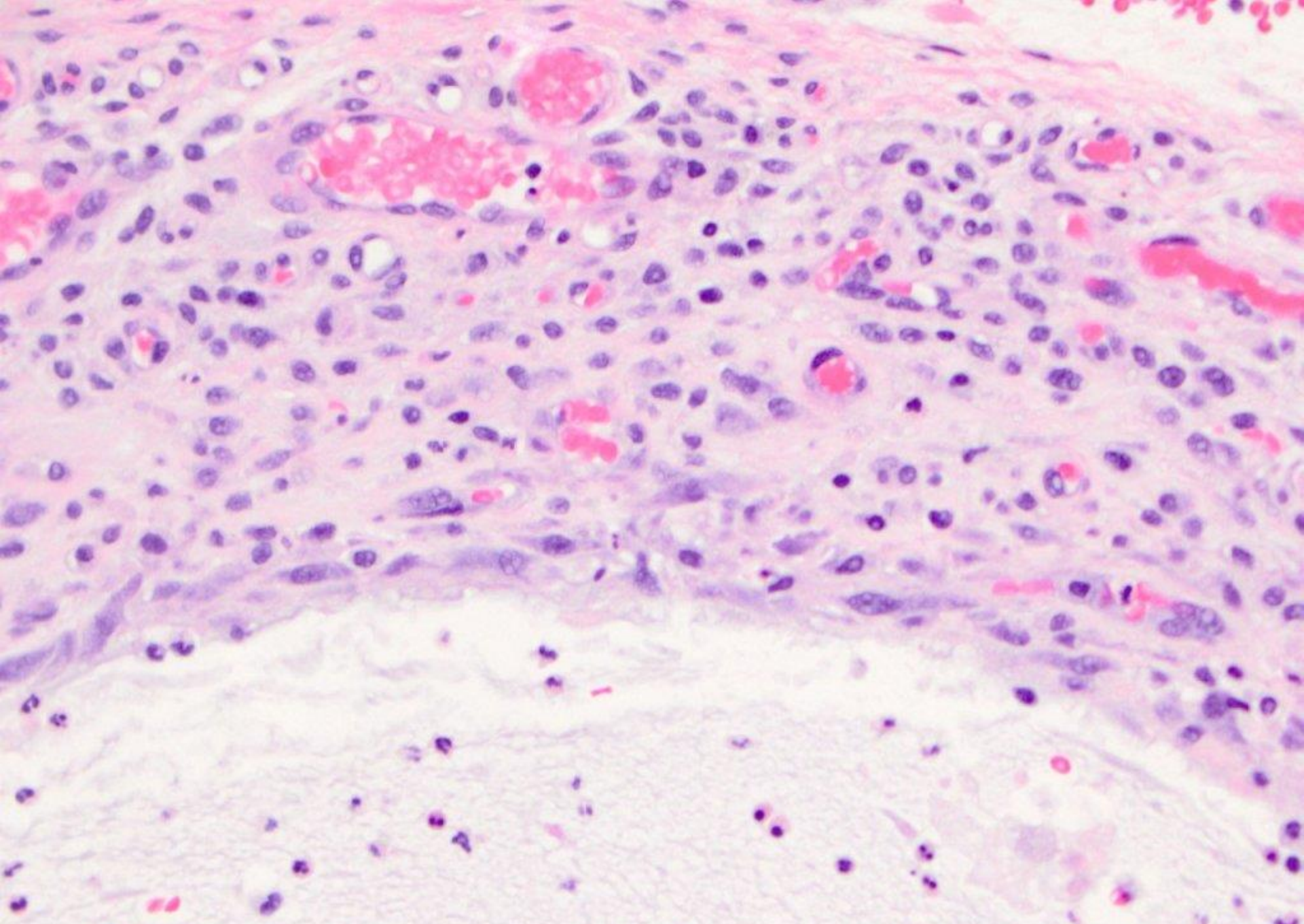
DAVID E. KLINGMAN, DMD

Diplomate, American Board of Oral and Maxillofacial Pathology

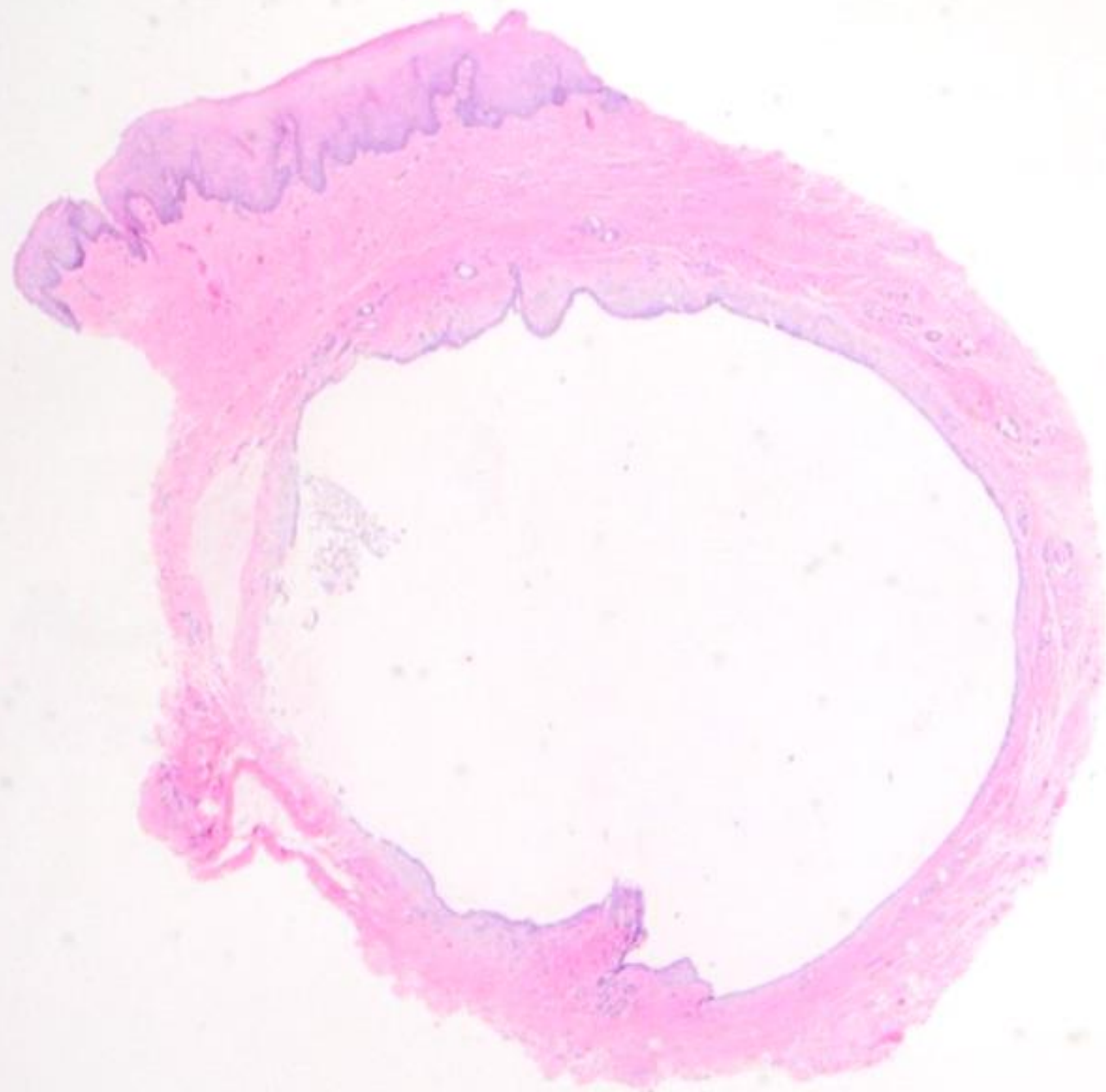
Diplomate, American Board of General Dentistry

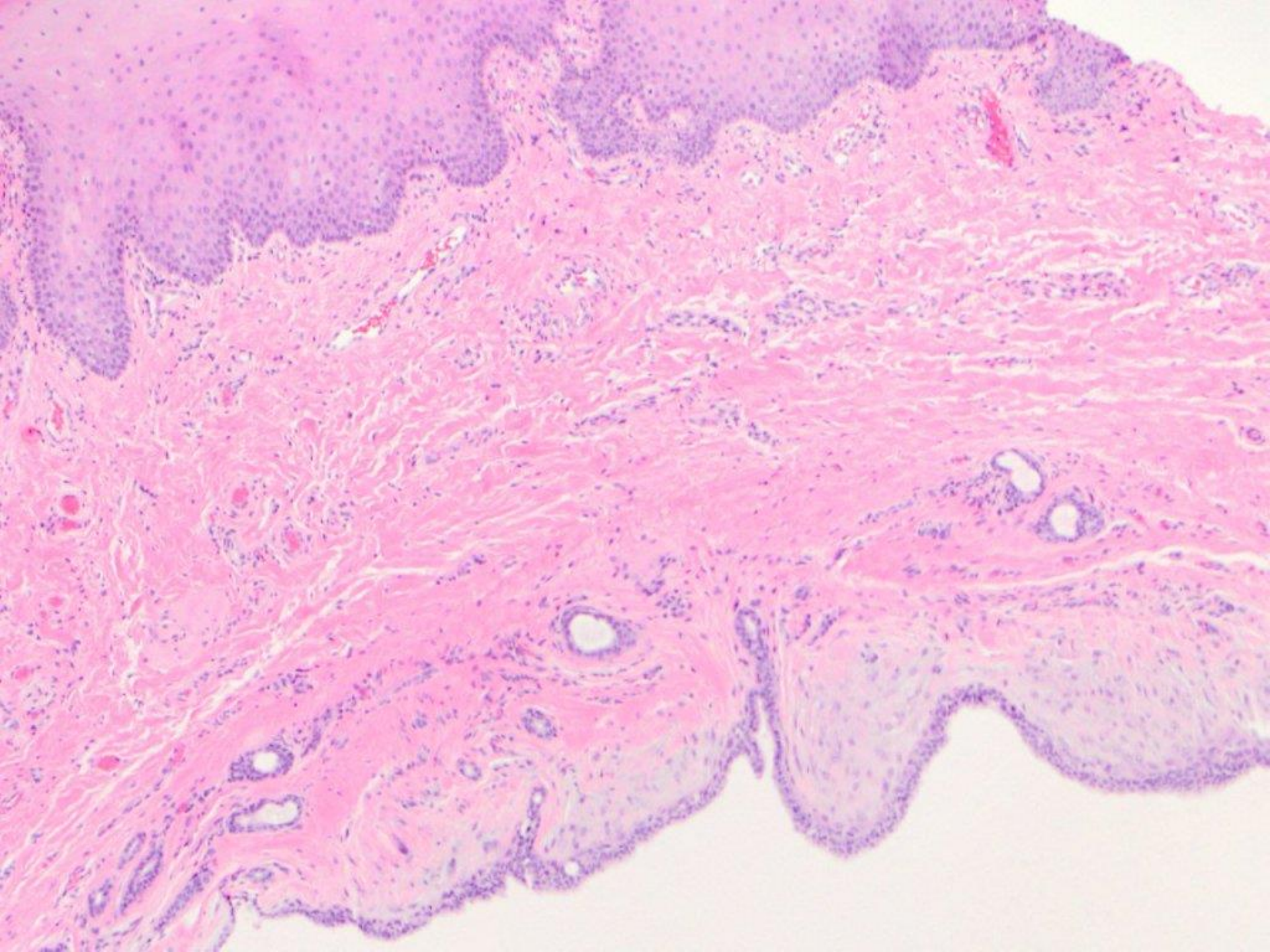


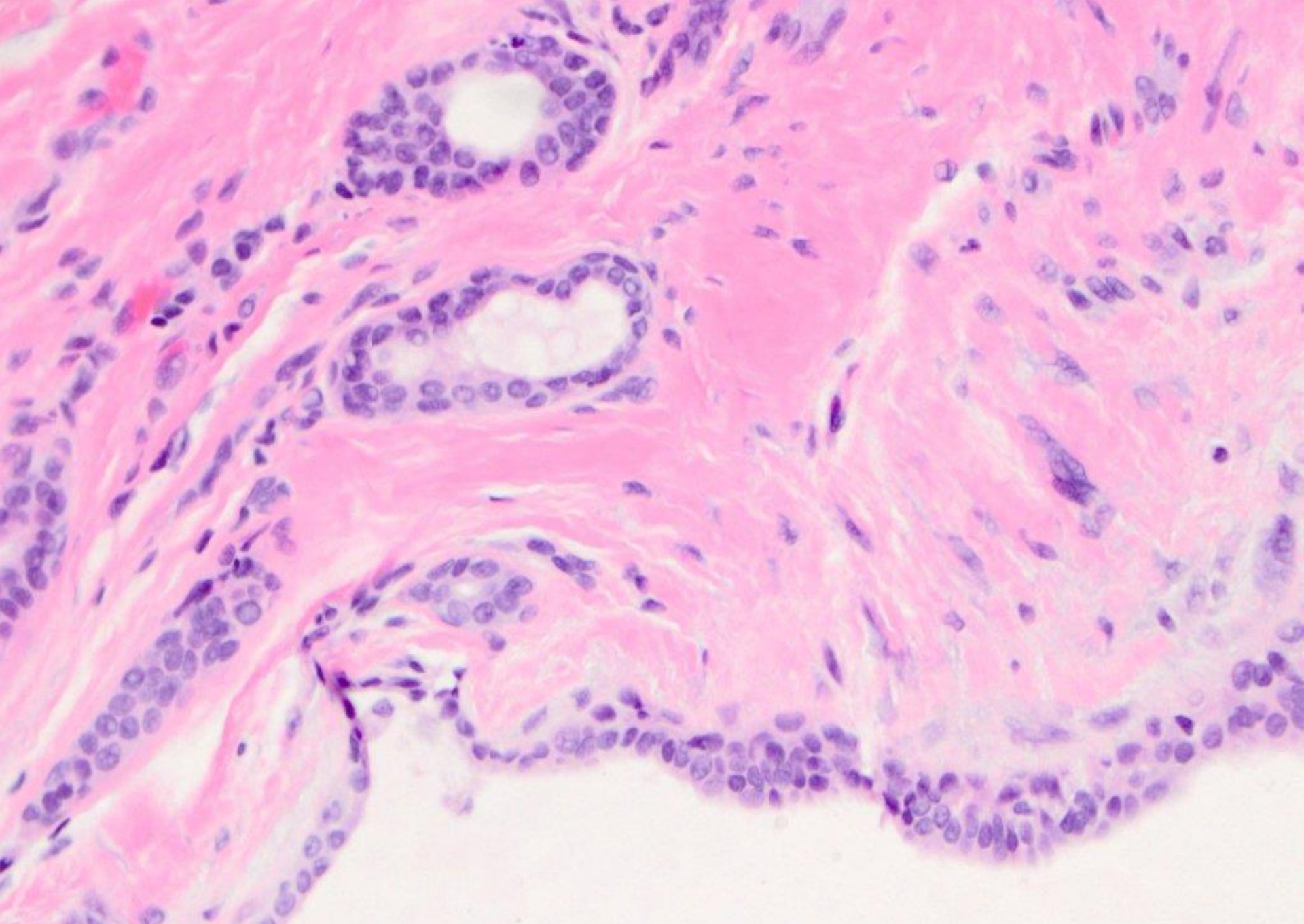




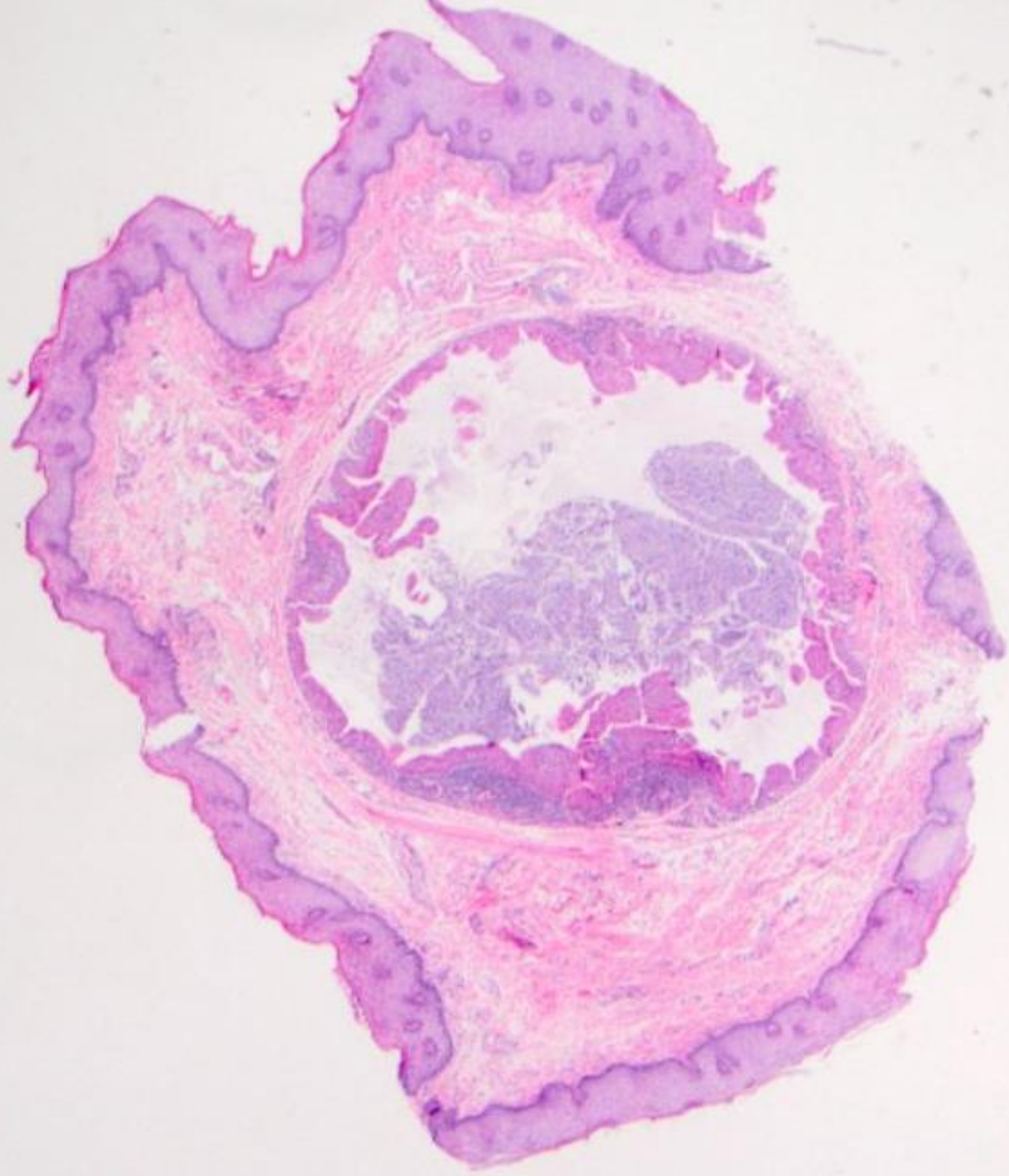
mucocoele

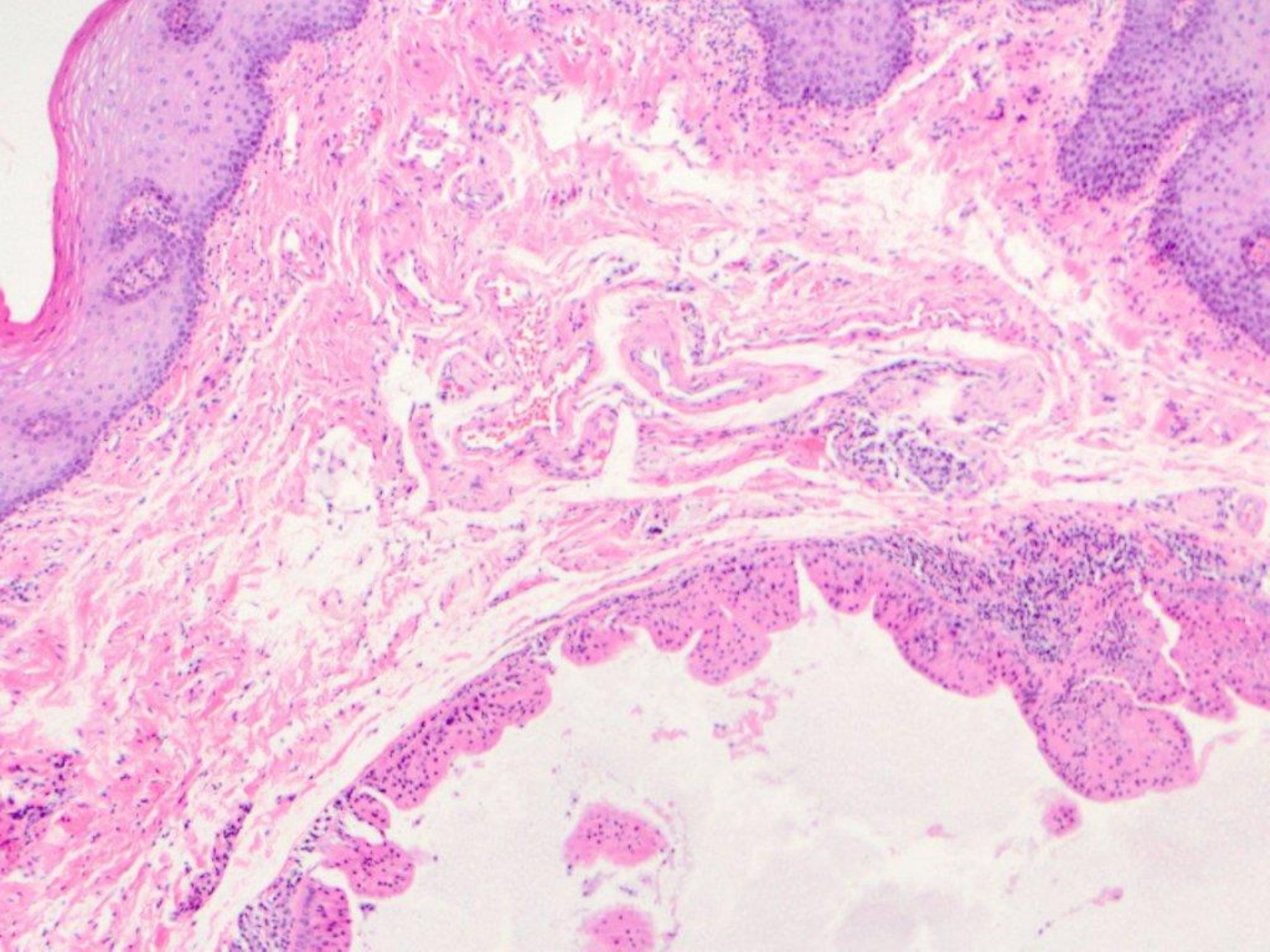


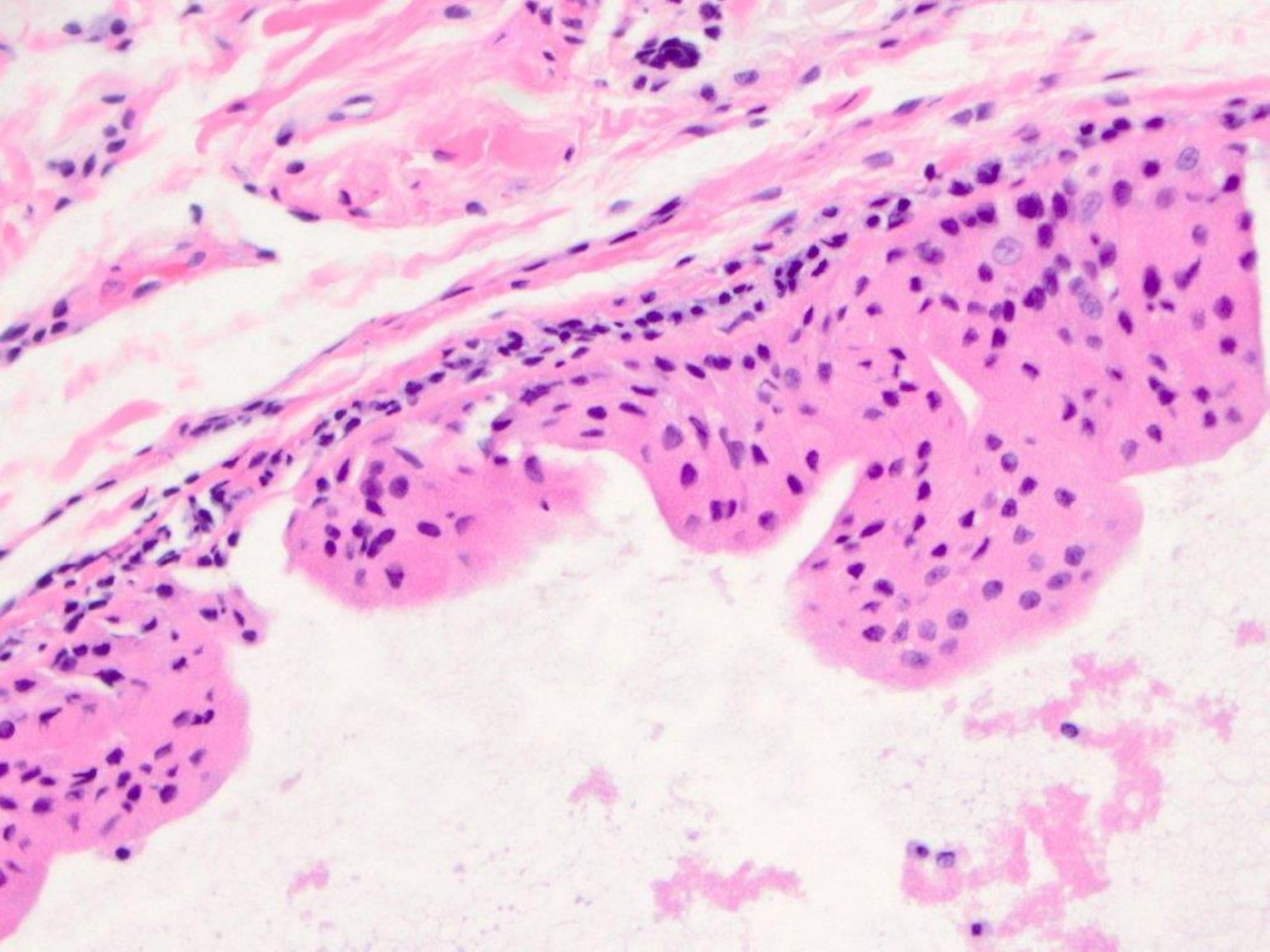


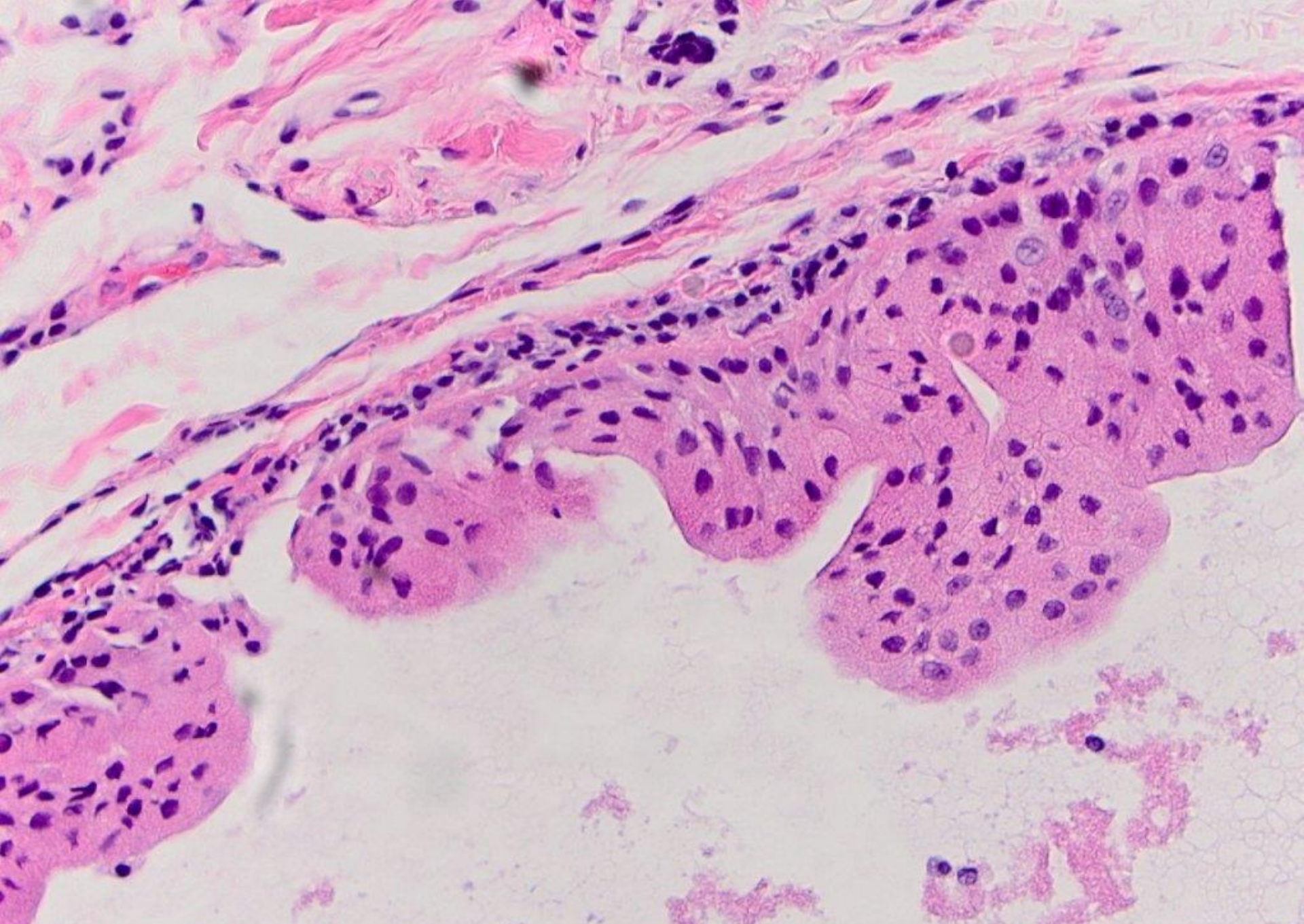


salivary duct cyst

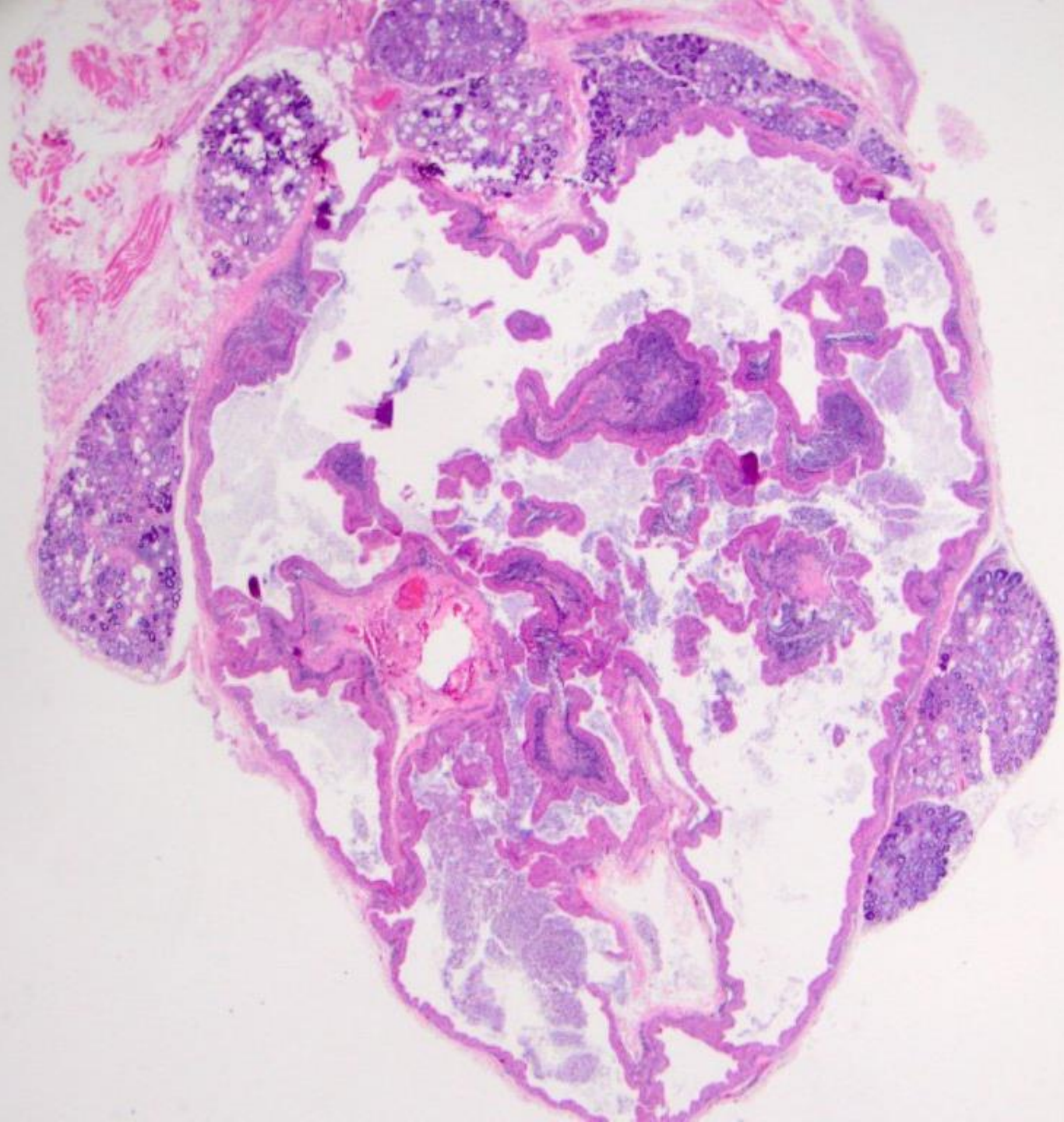


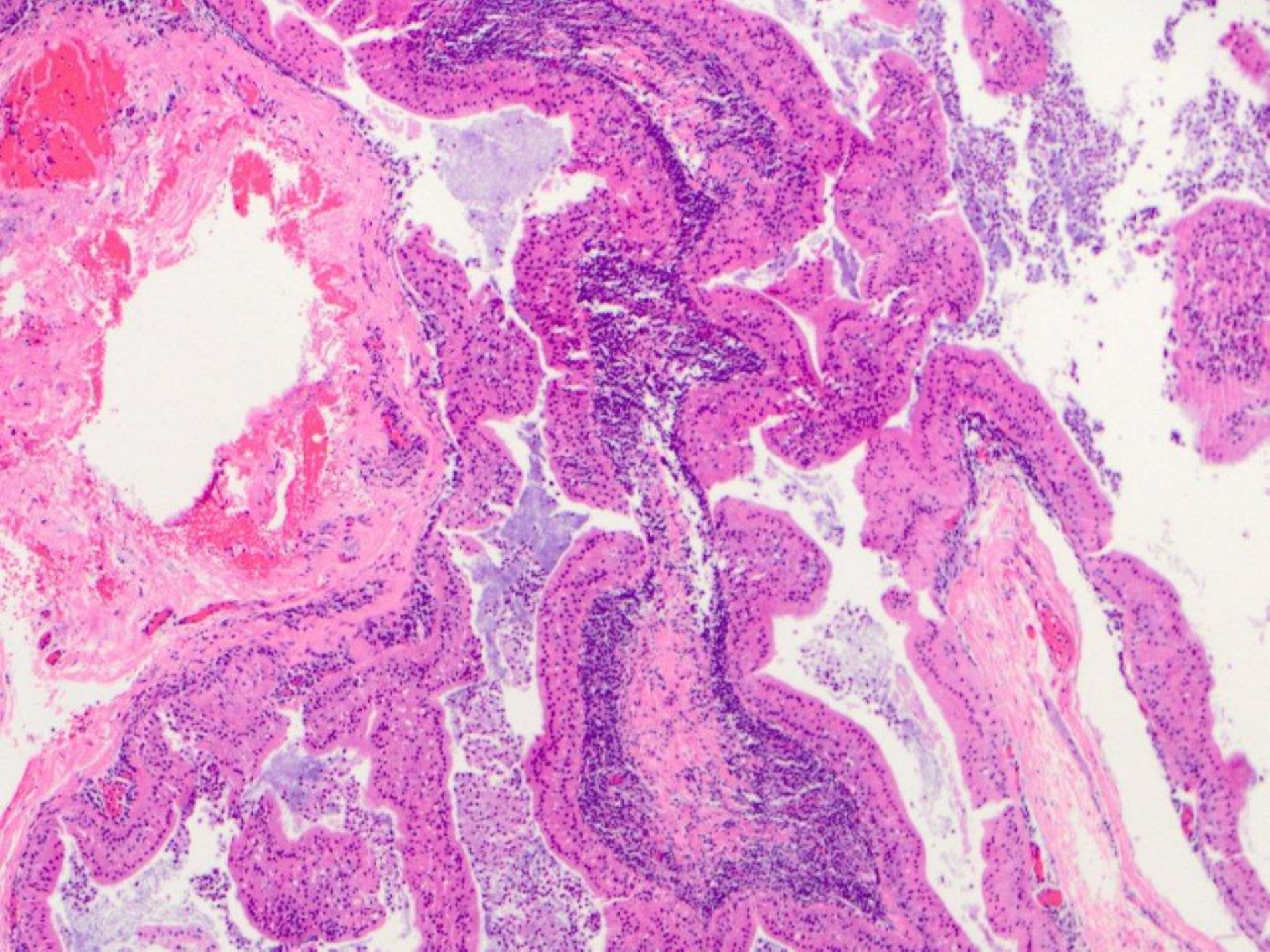


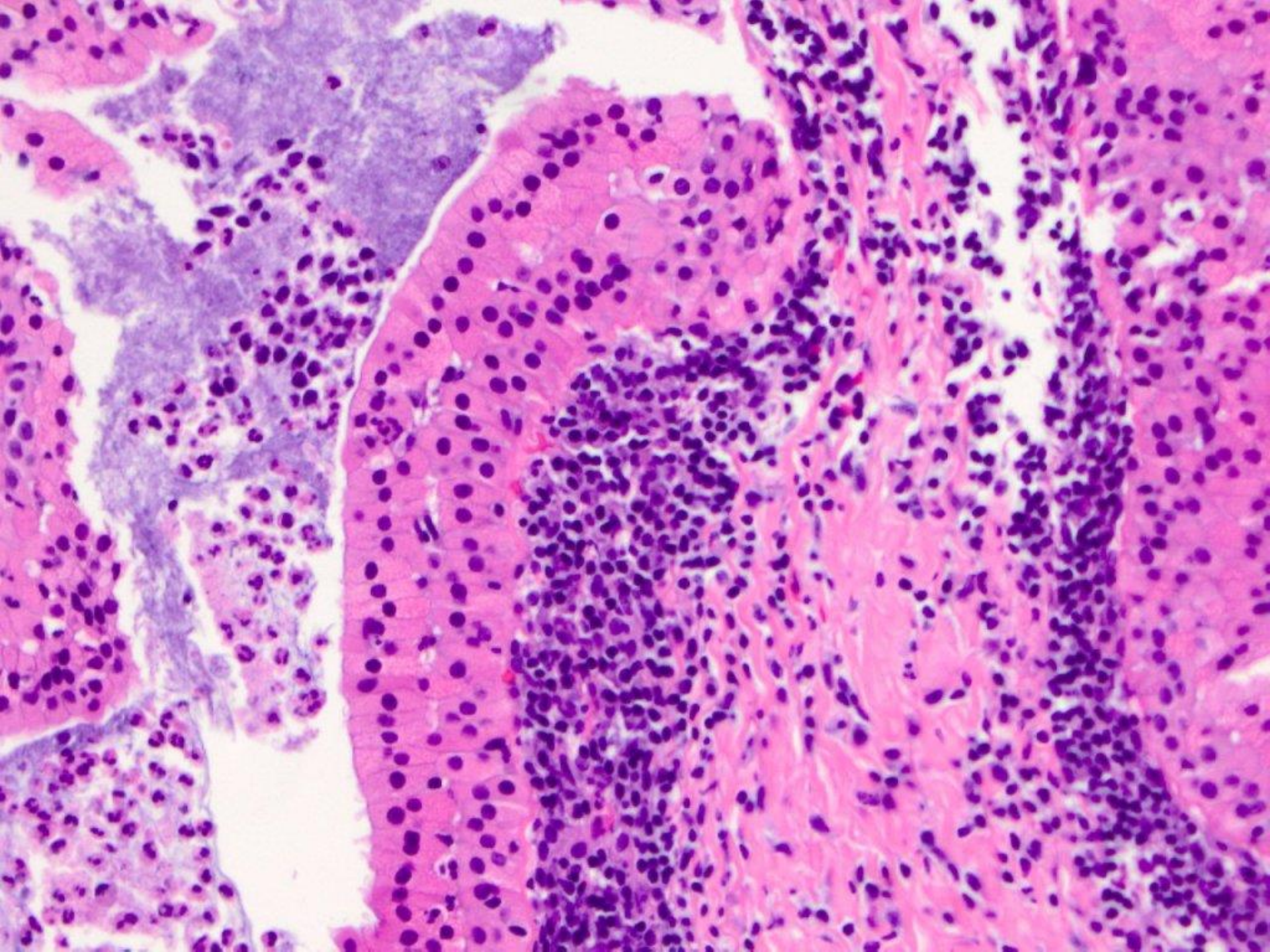


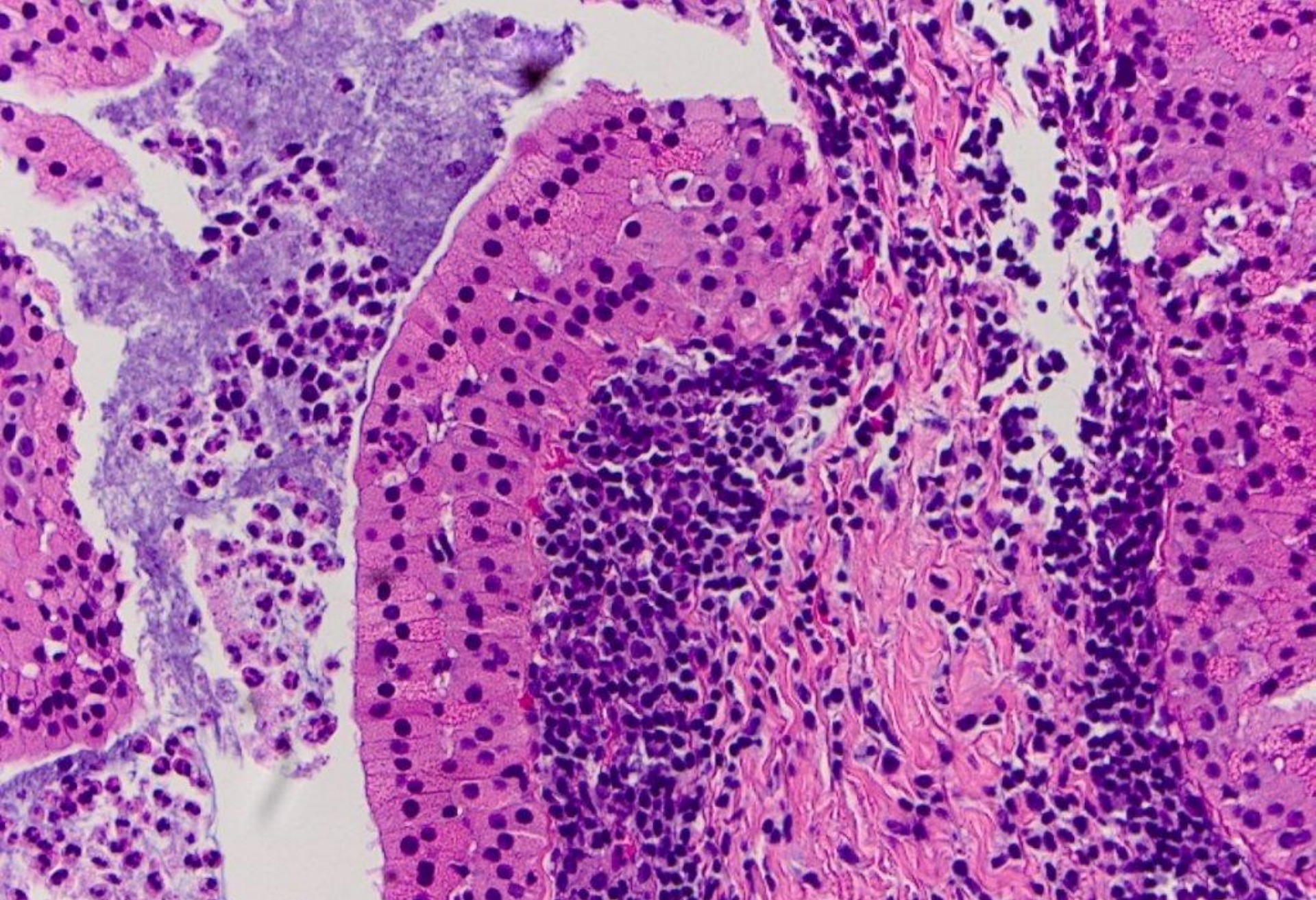


salivary duct cyst with oncocytic metaplasia

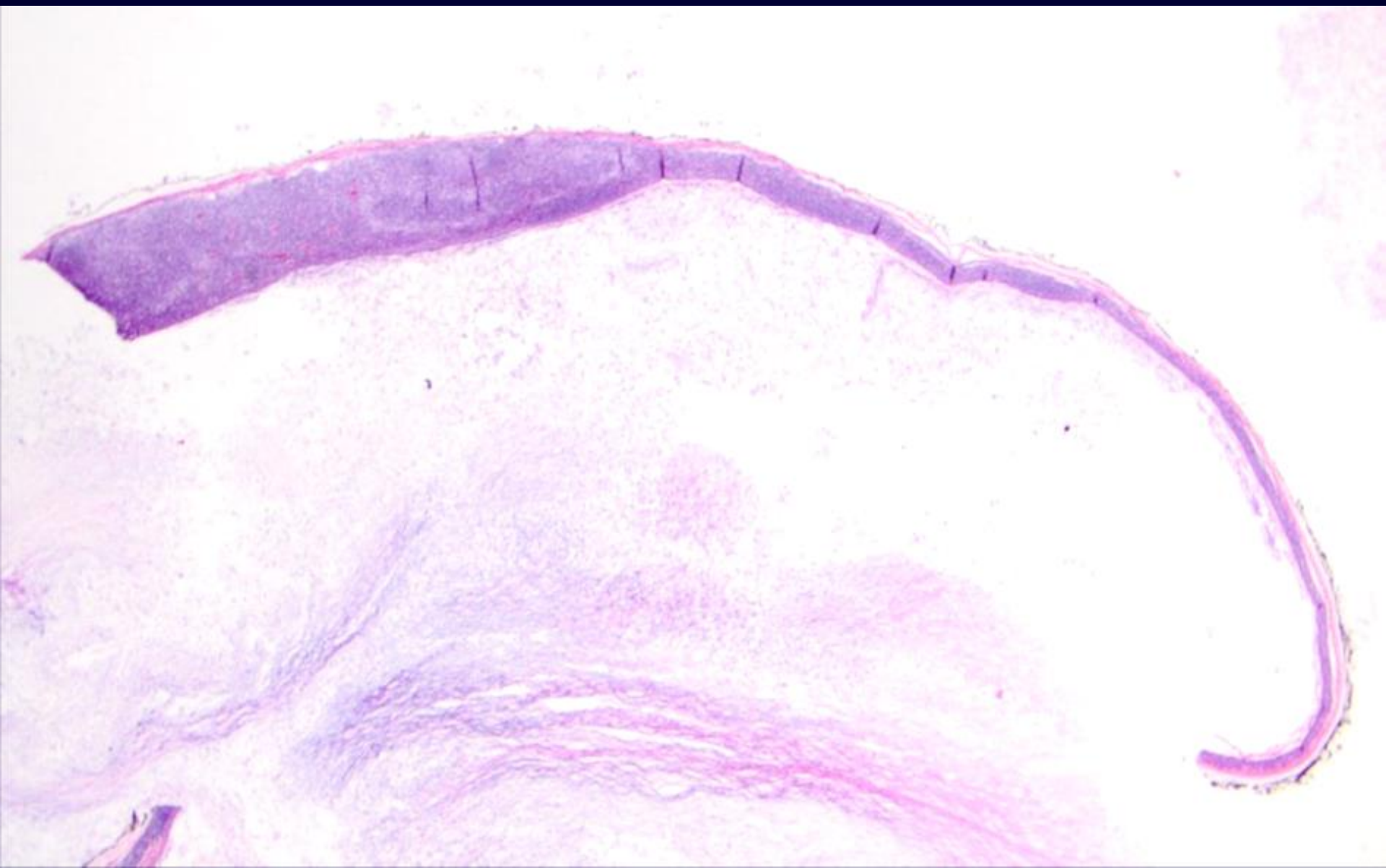


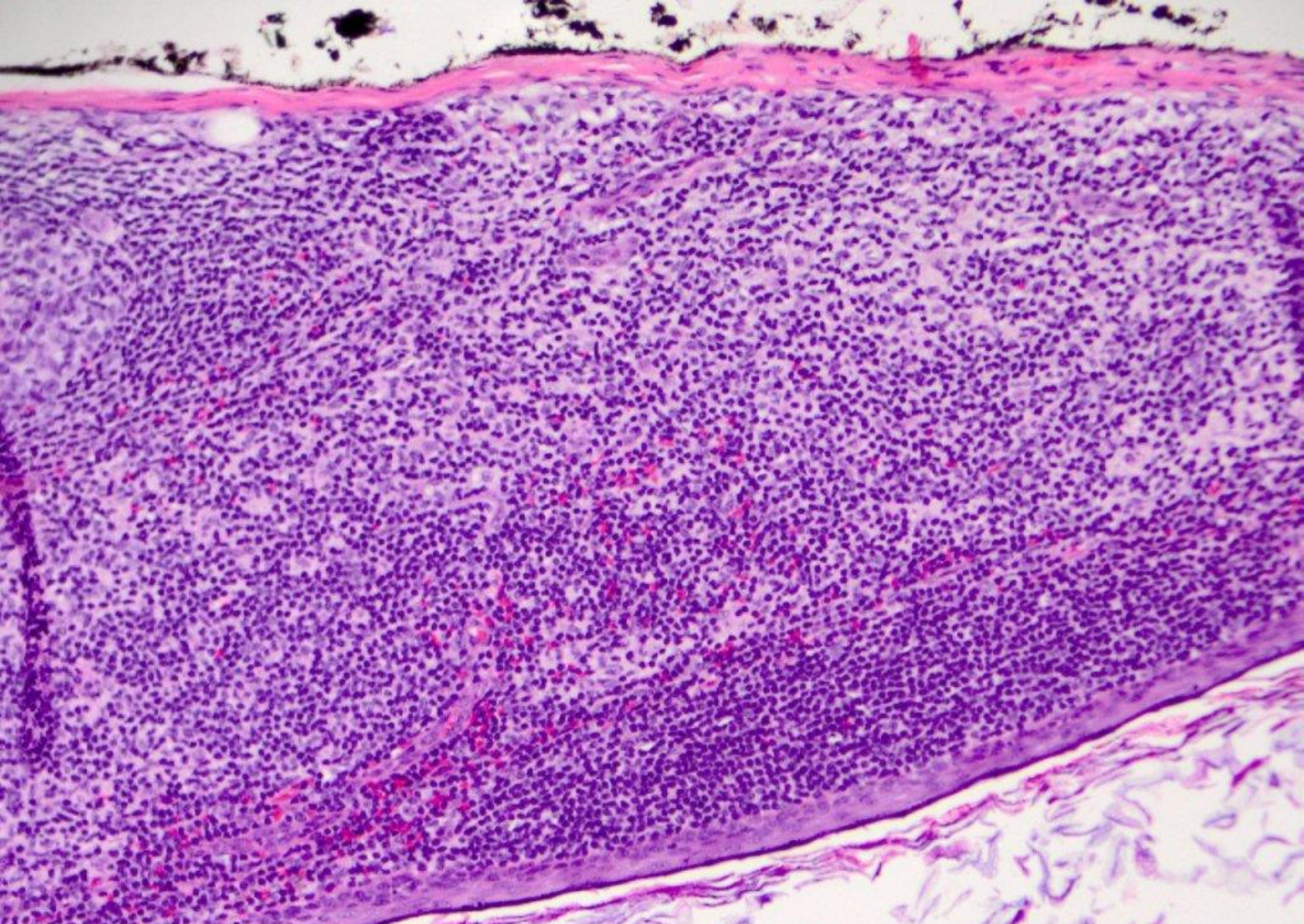




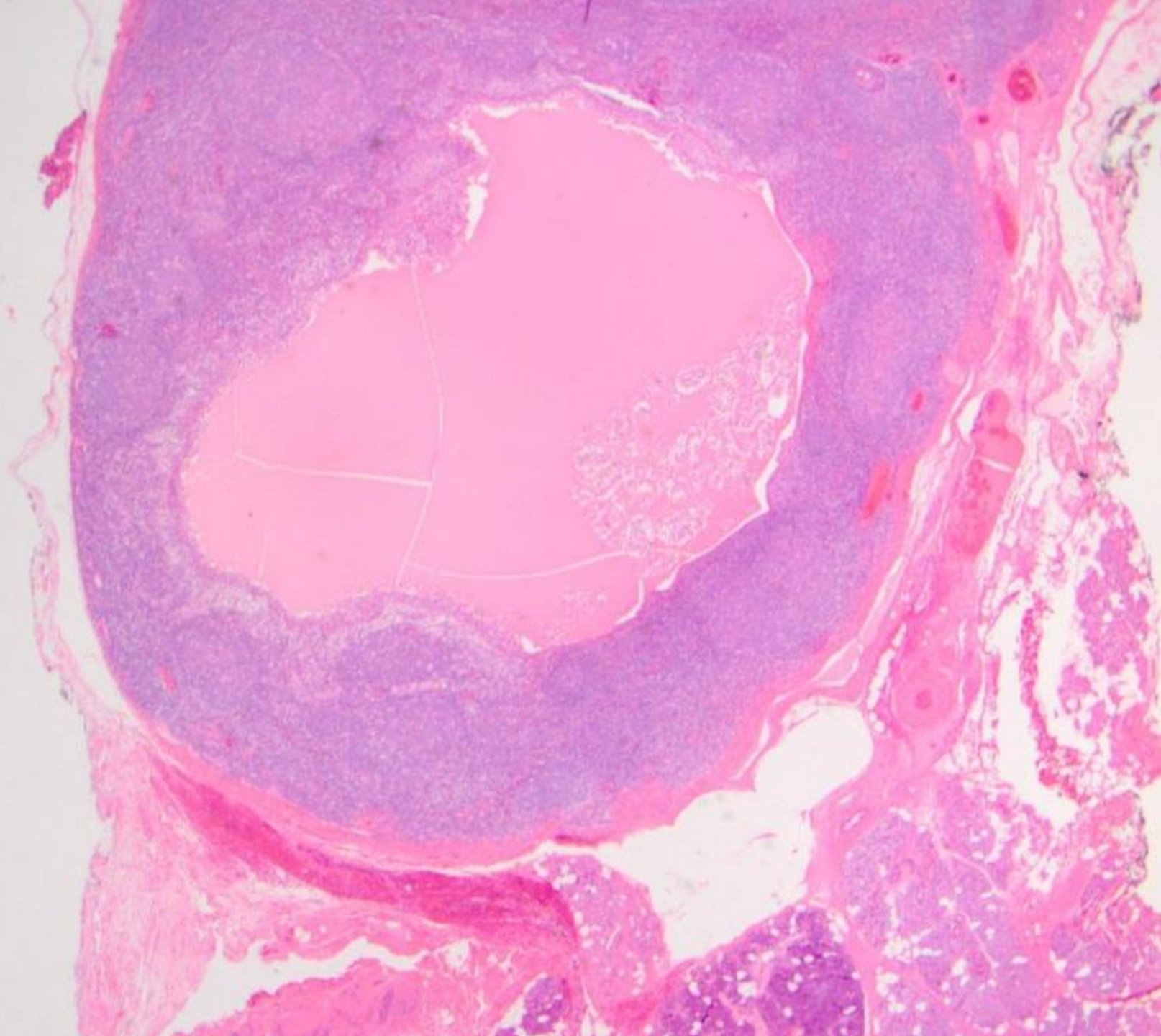


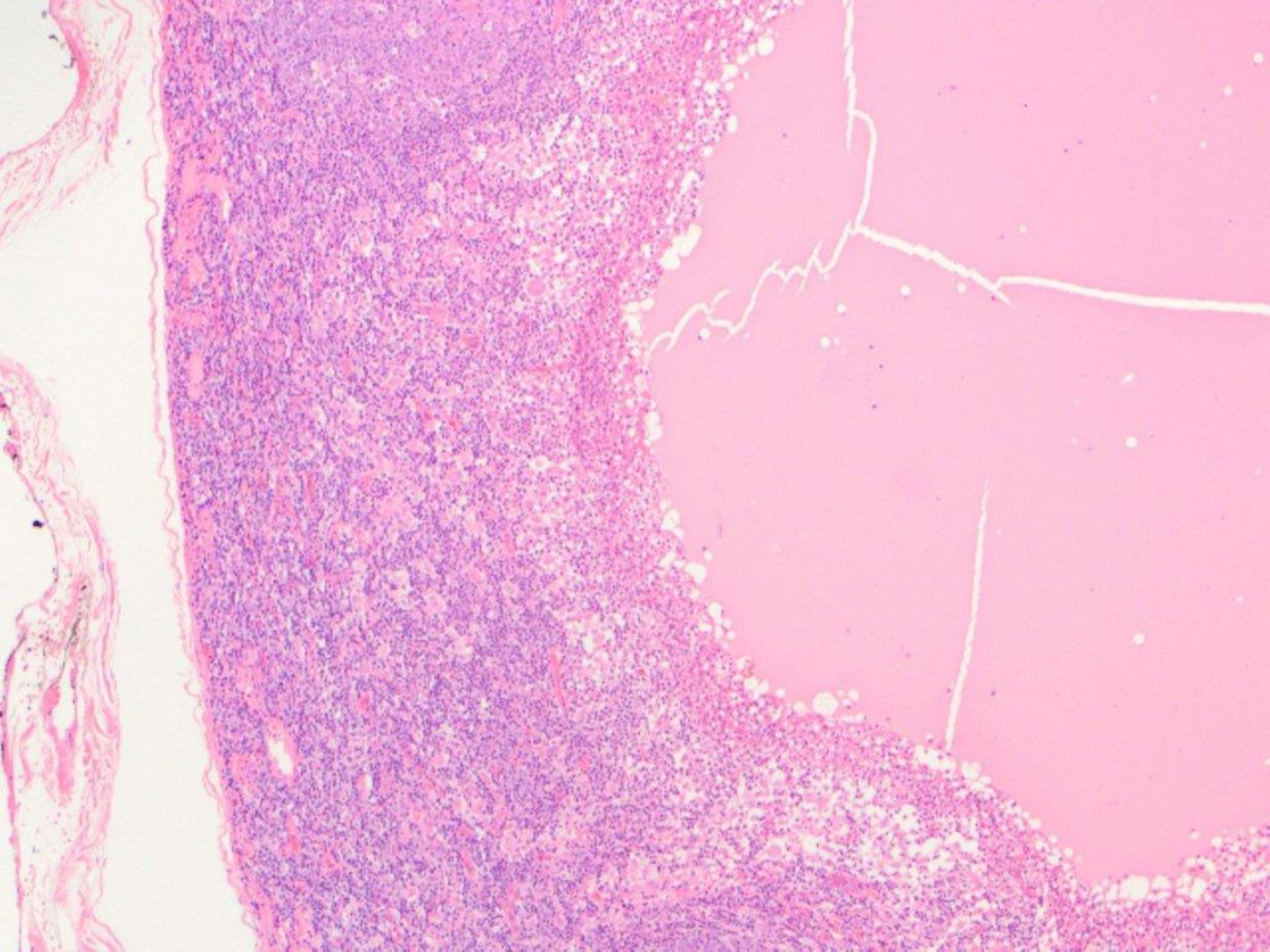
Oncocytic papillary cystadenoma with lymphoid stroma
[buccal mucosa; if this was in the parotid, it would be a Warthin tumor]

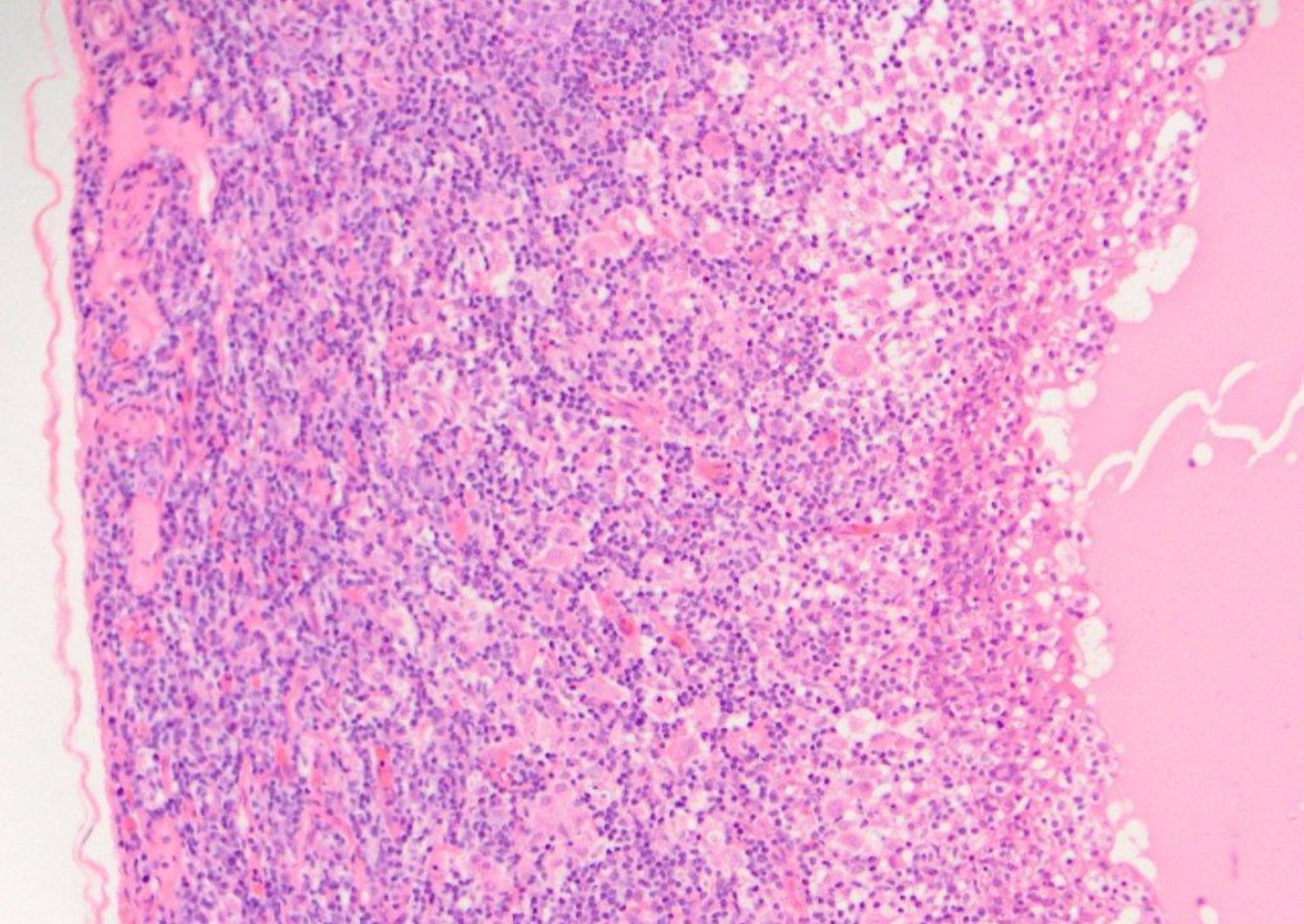




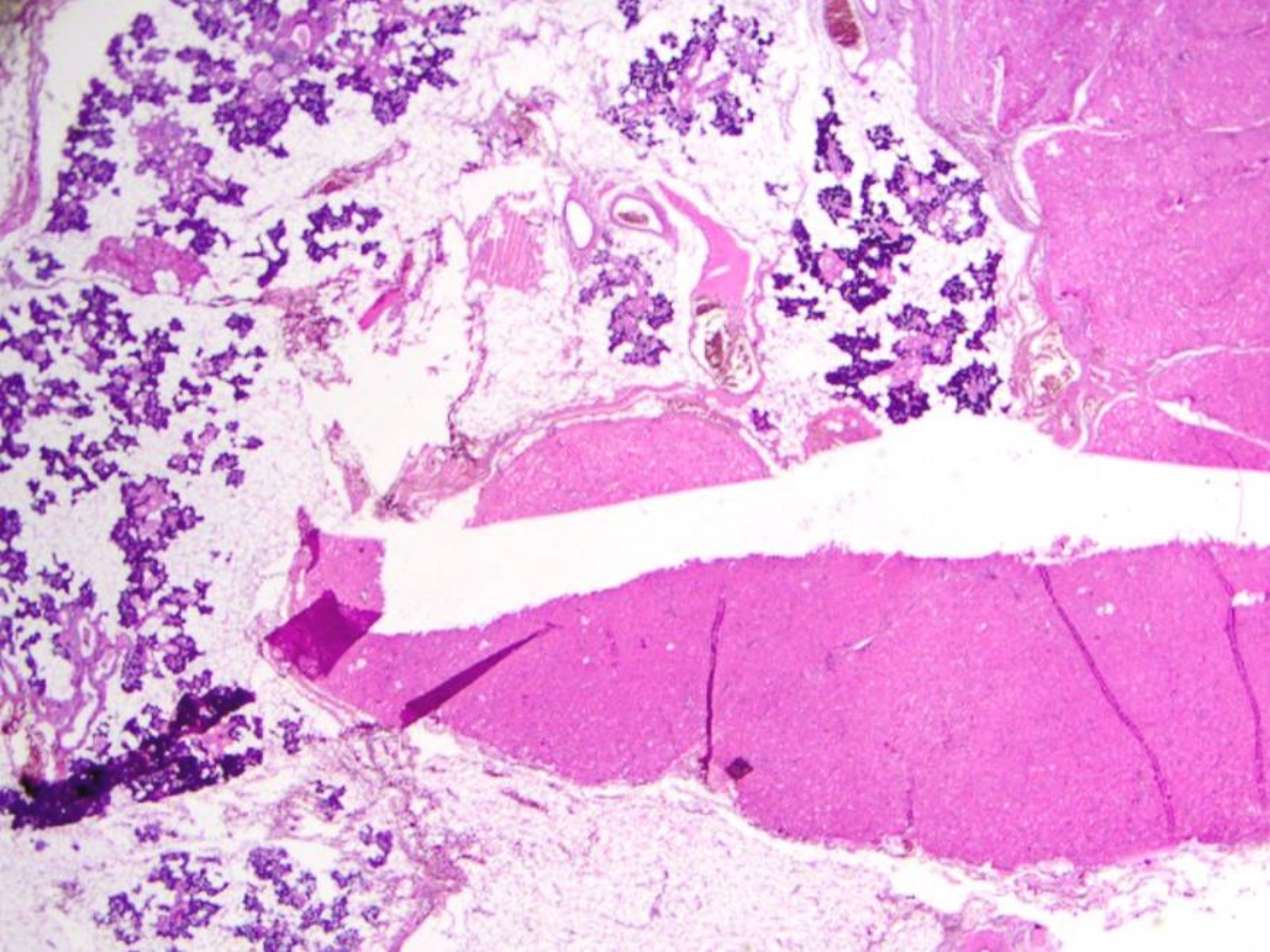
lymphoepithelial cyst [in the parotid]

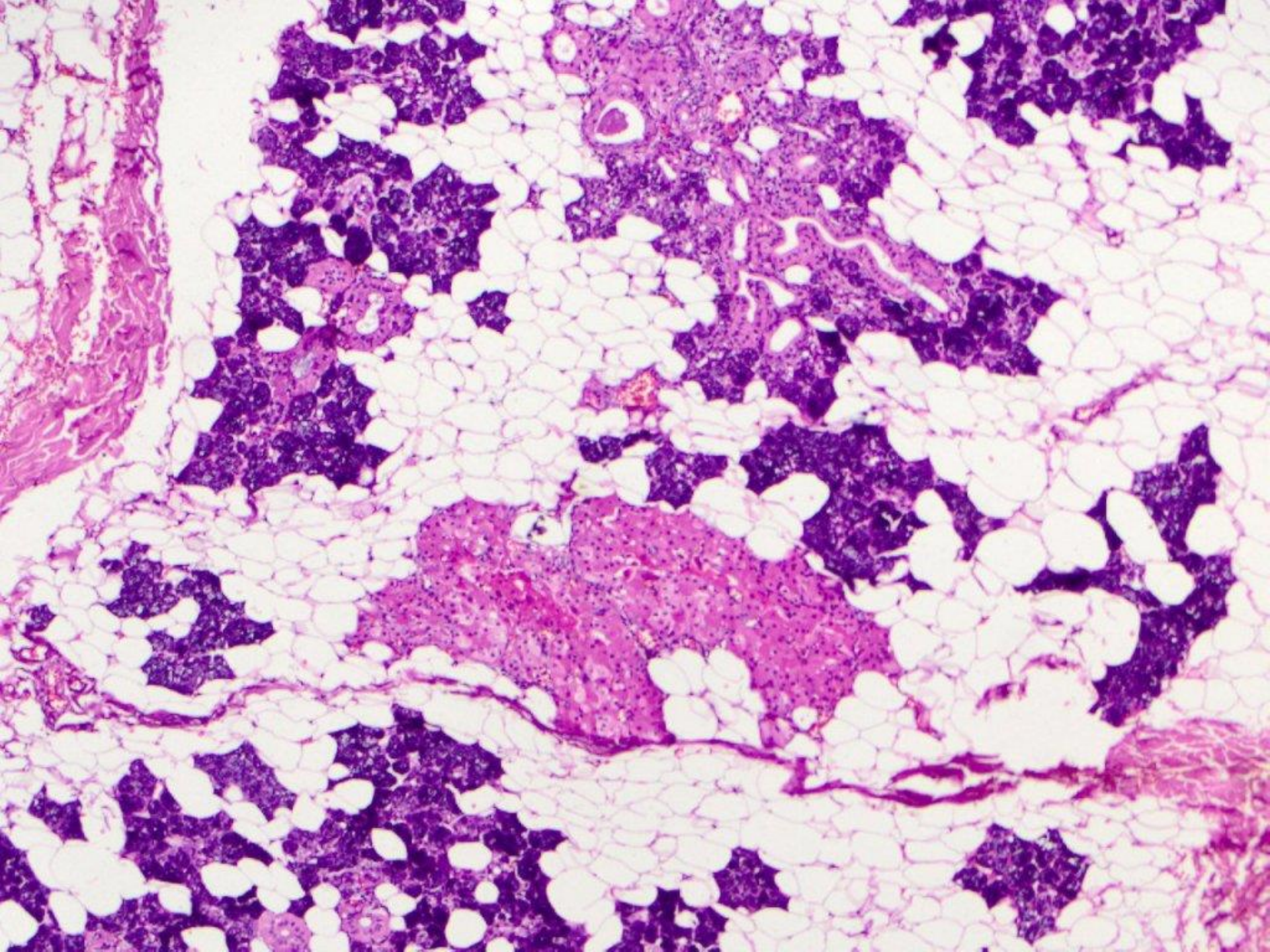


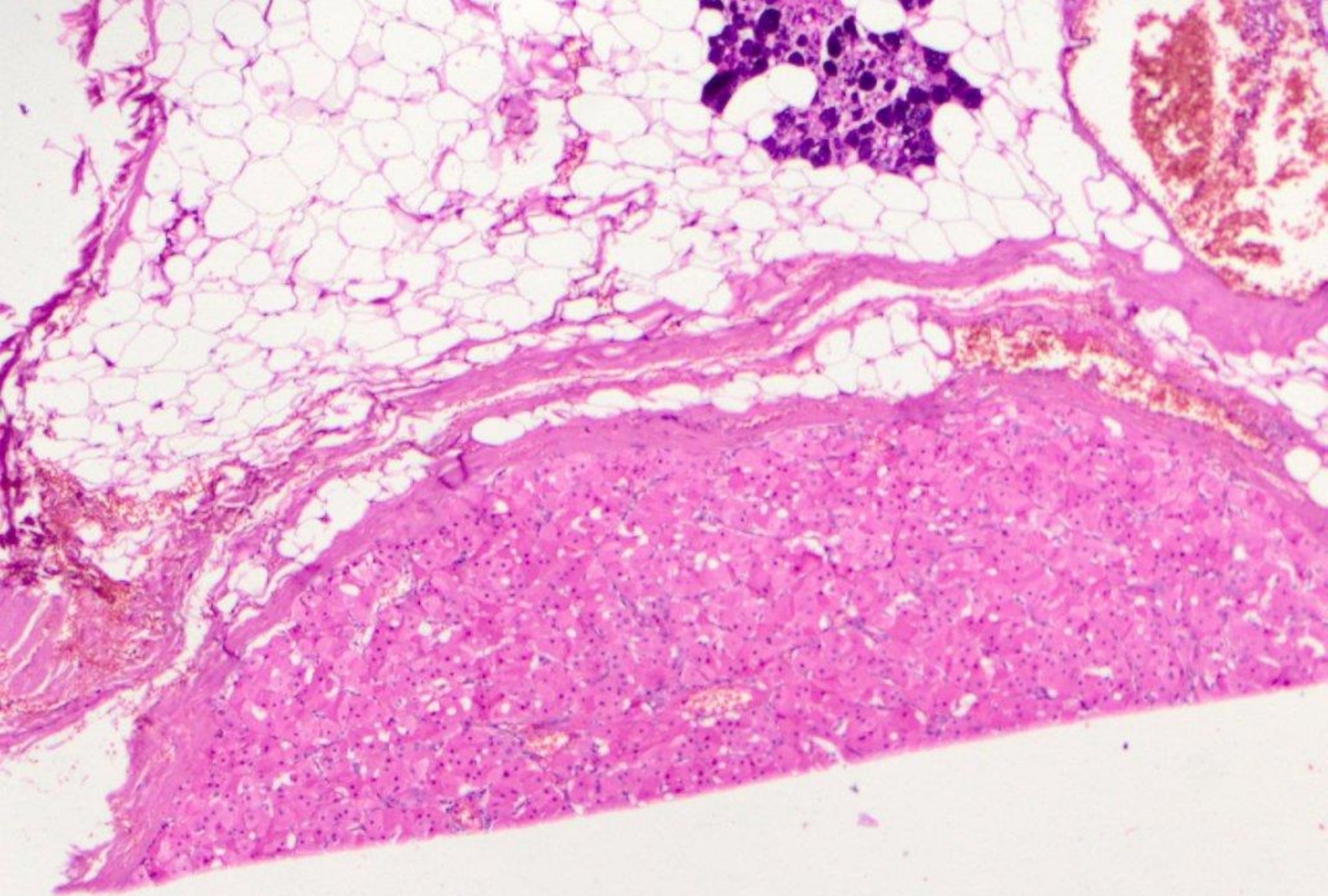


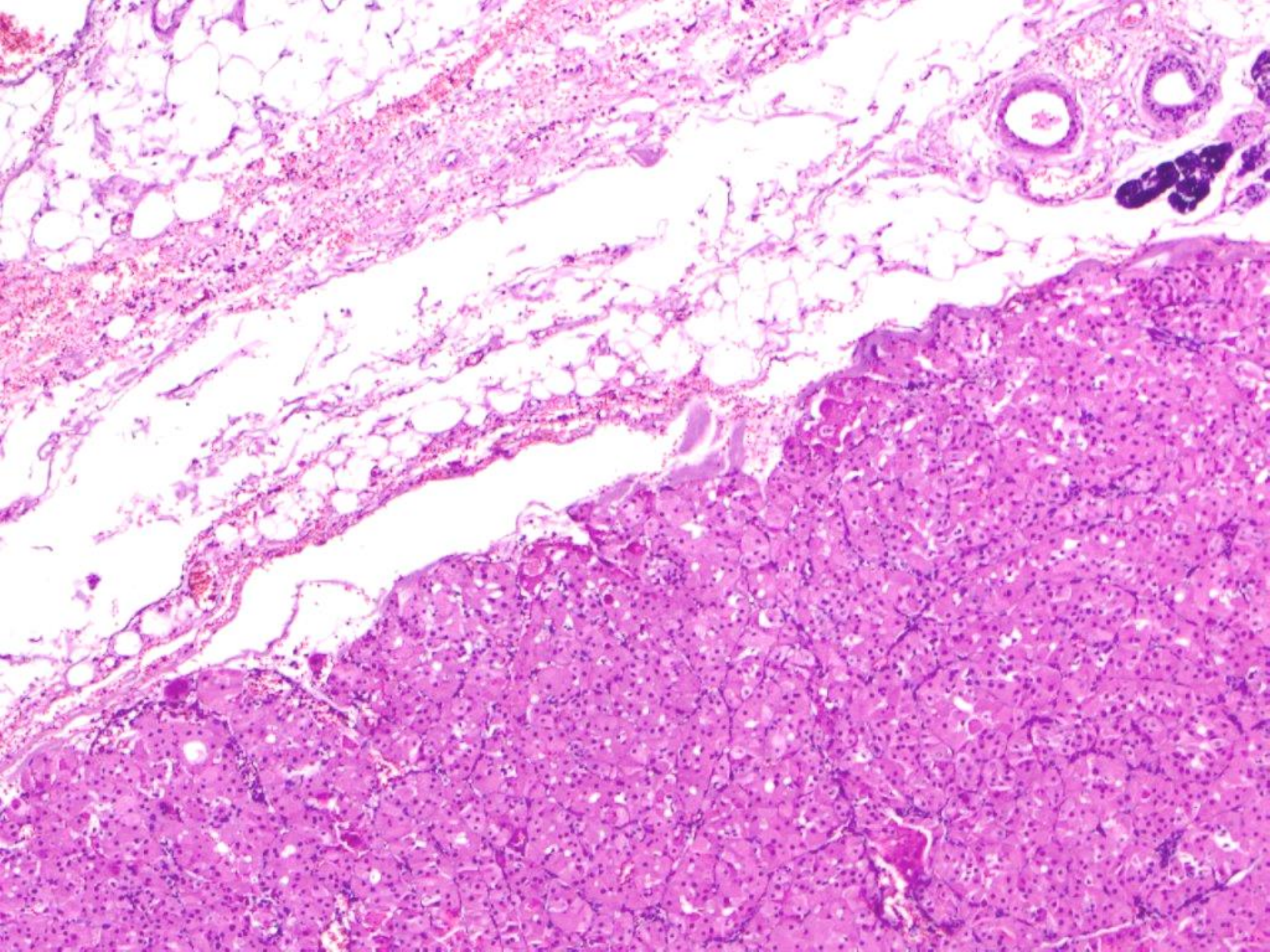


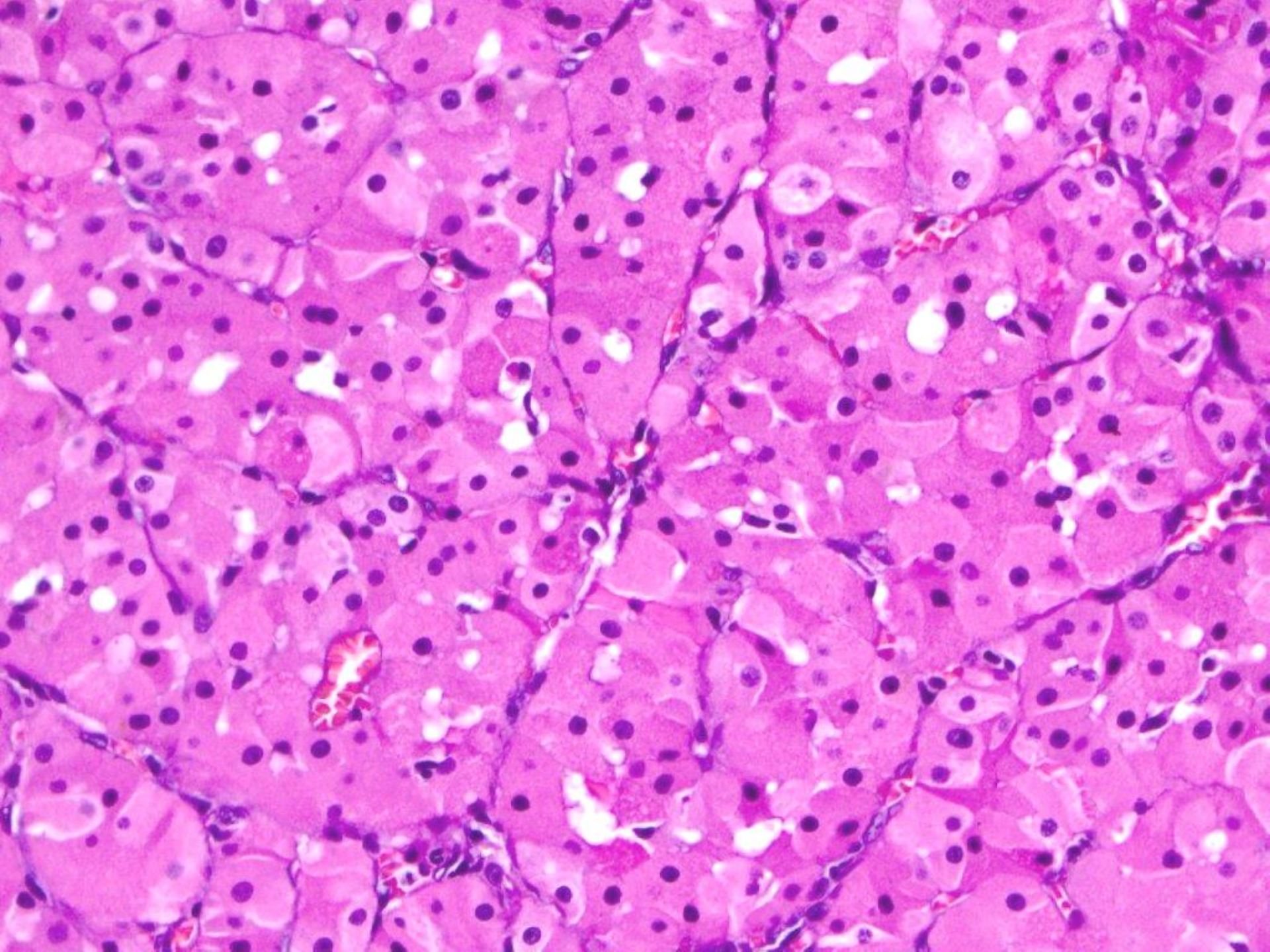
cystic salivary disease in an HIV+ individual

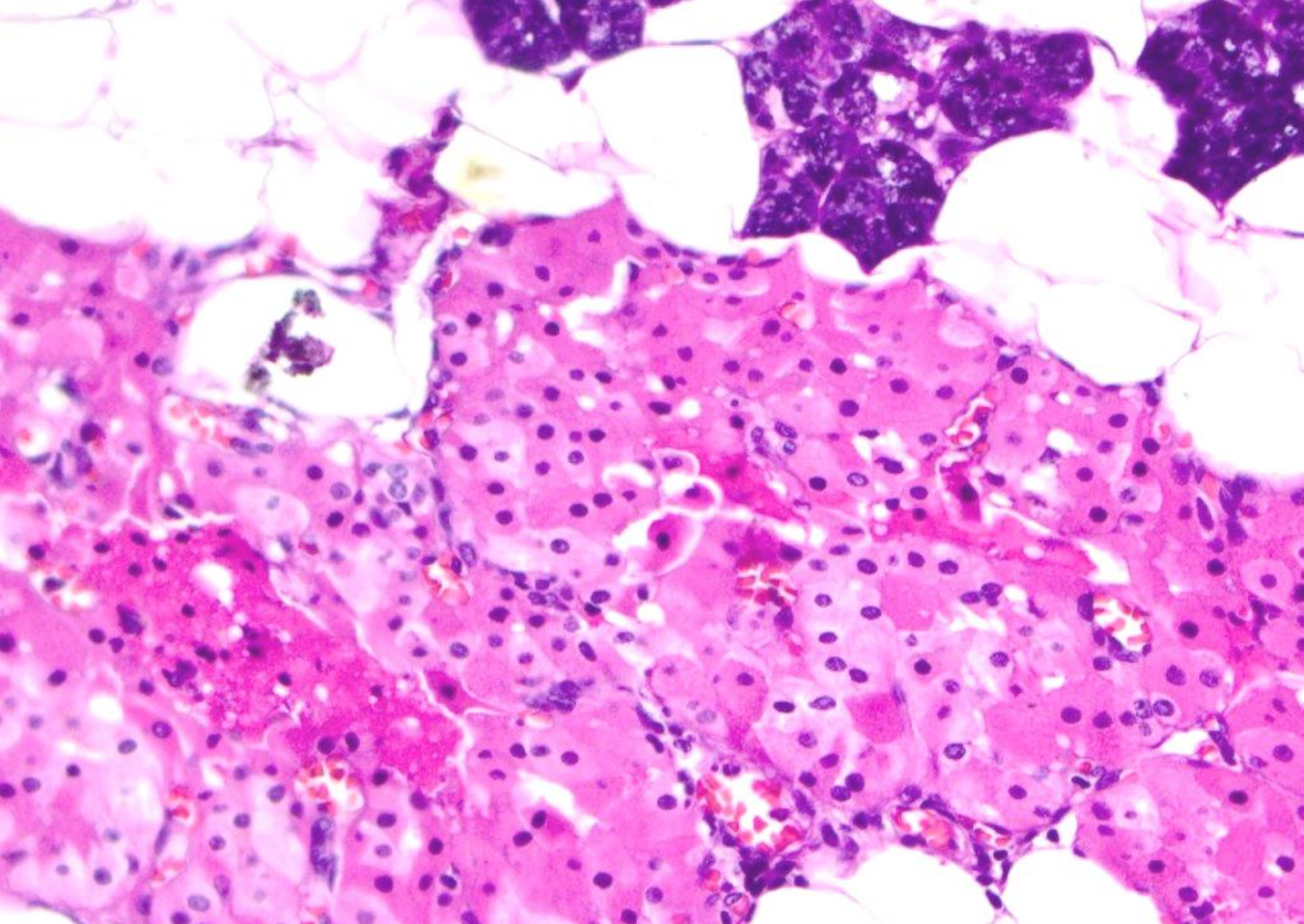




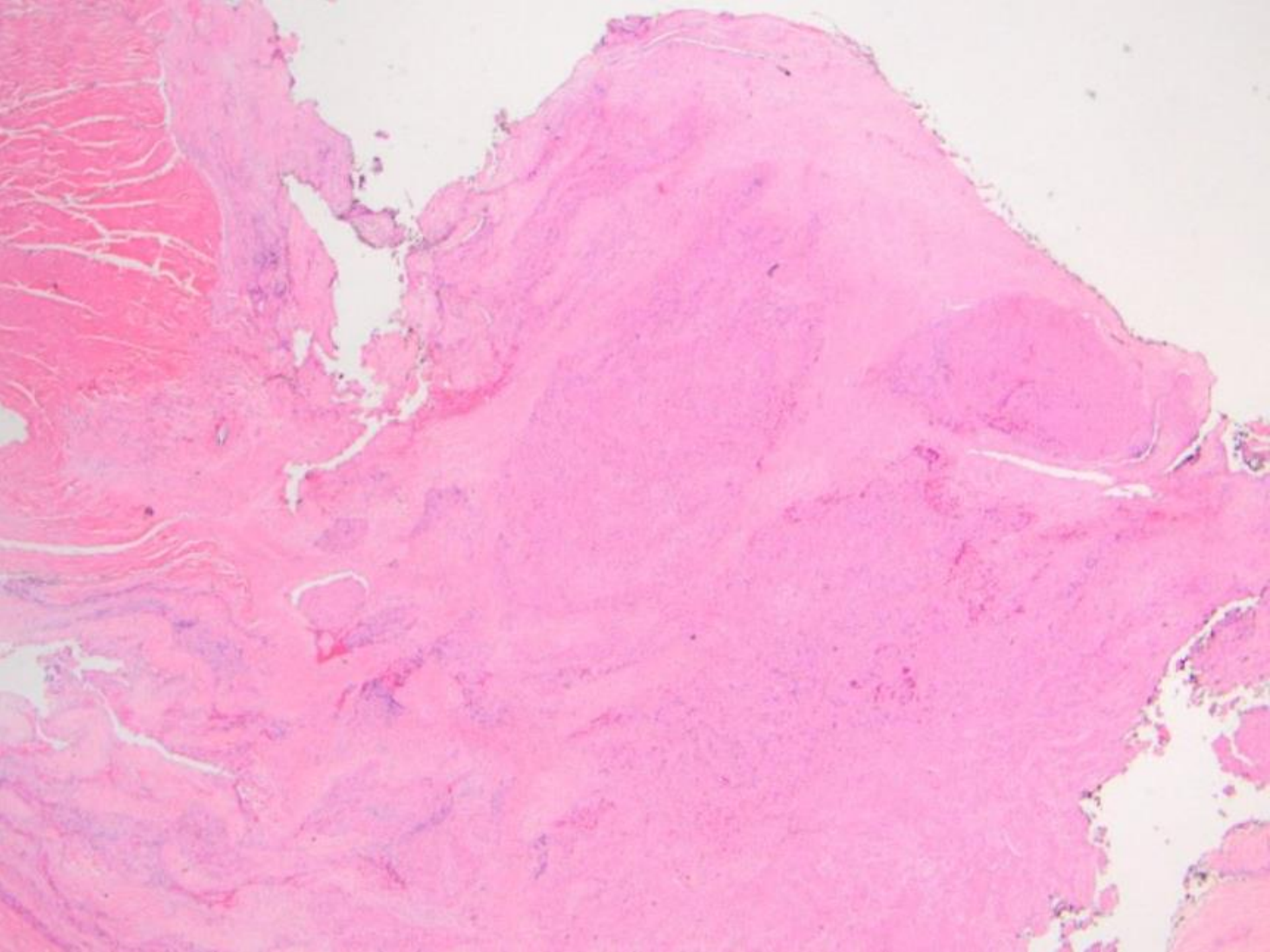


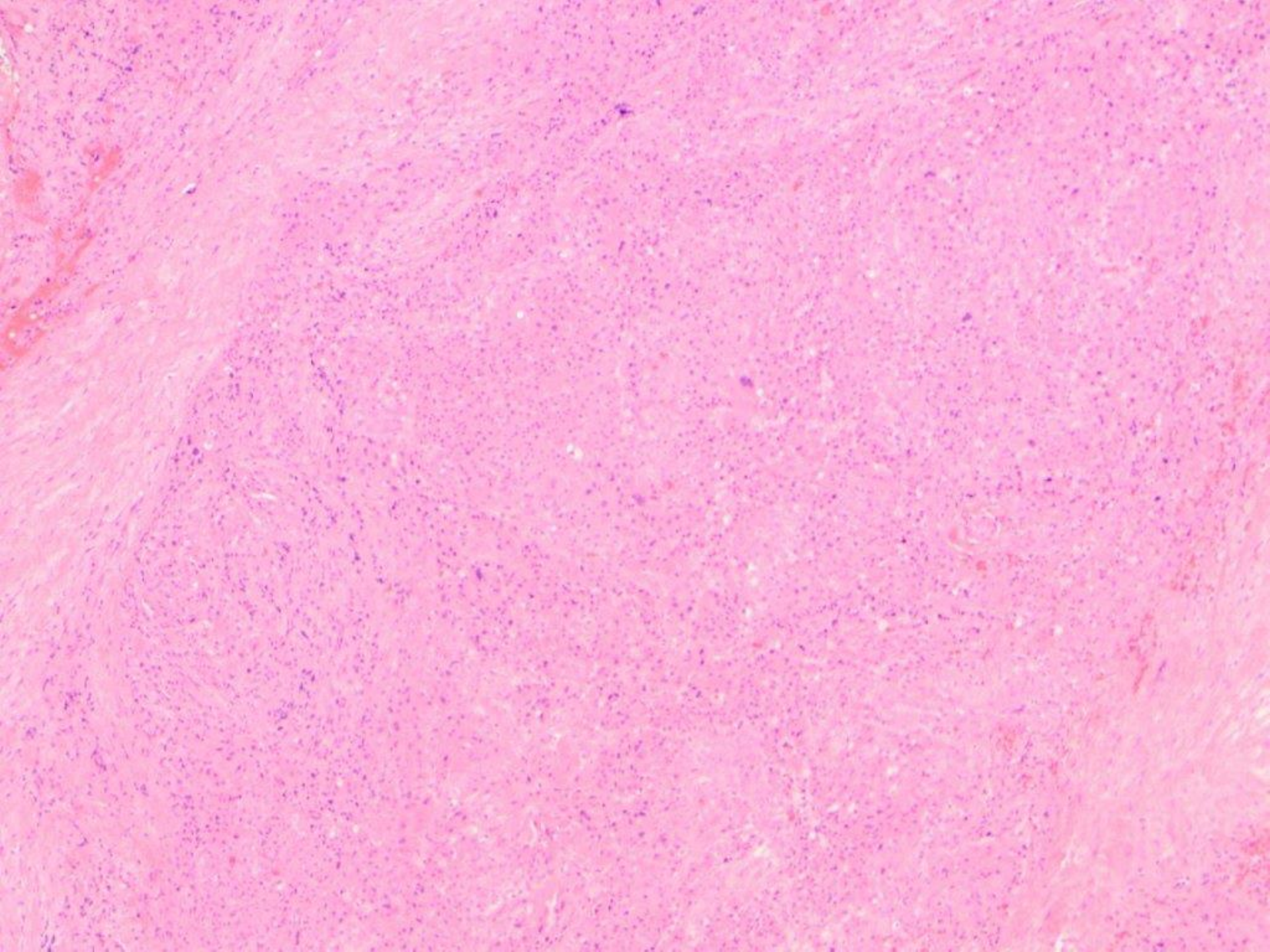


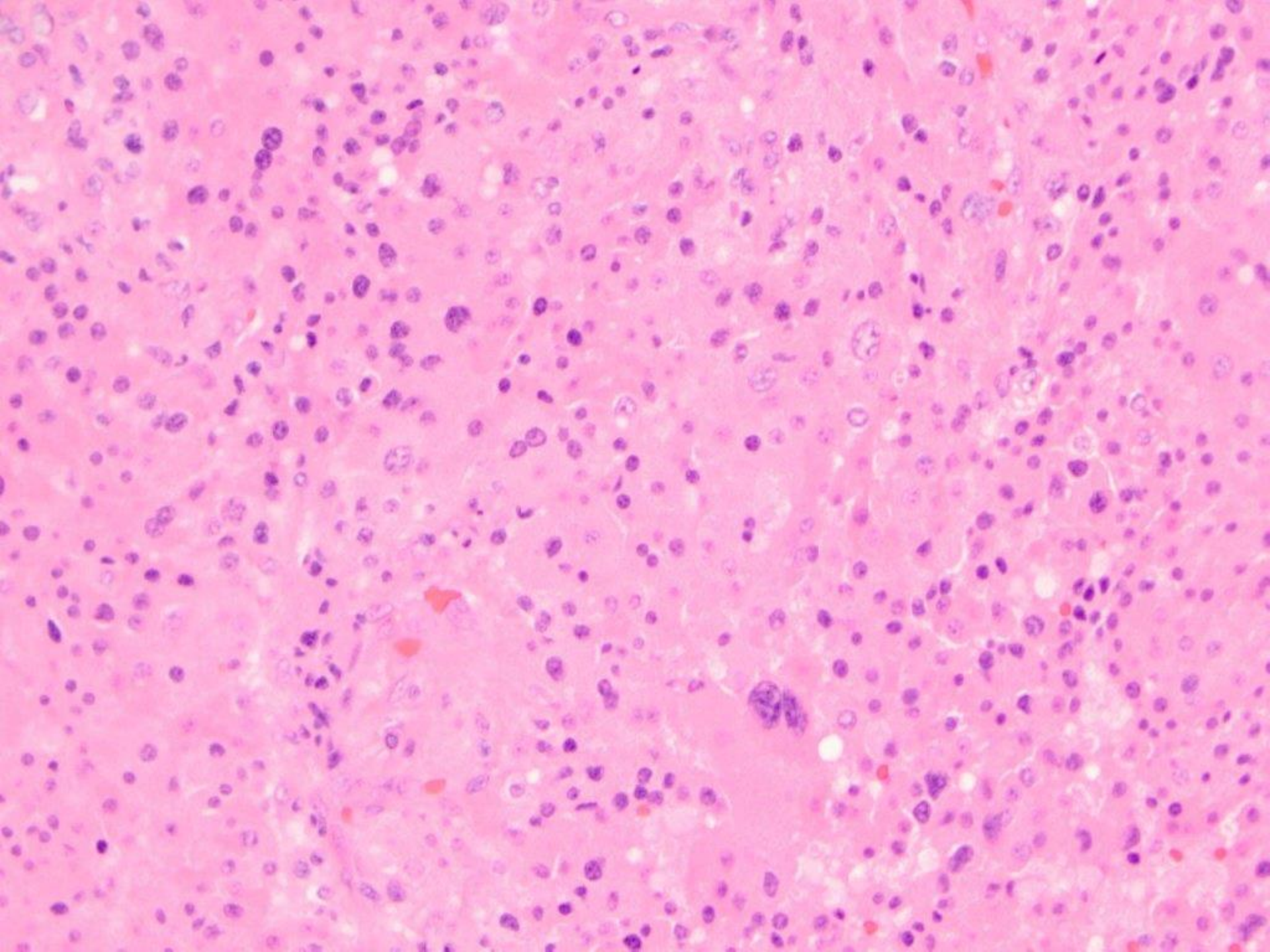


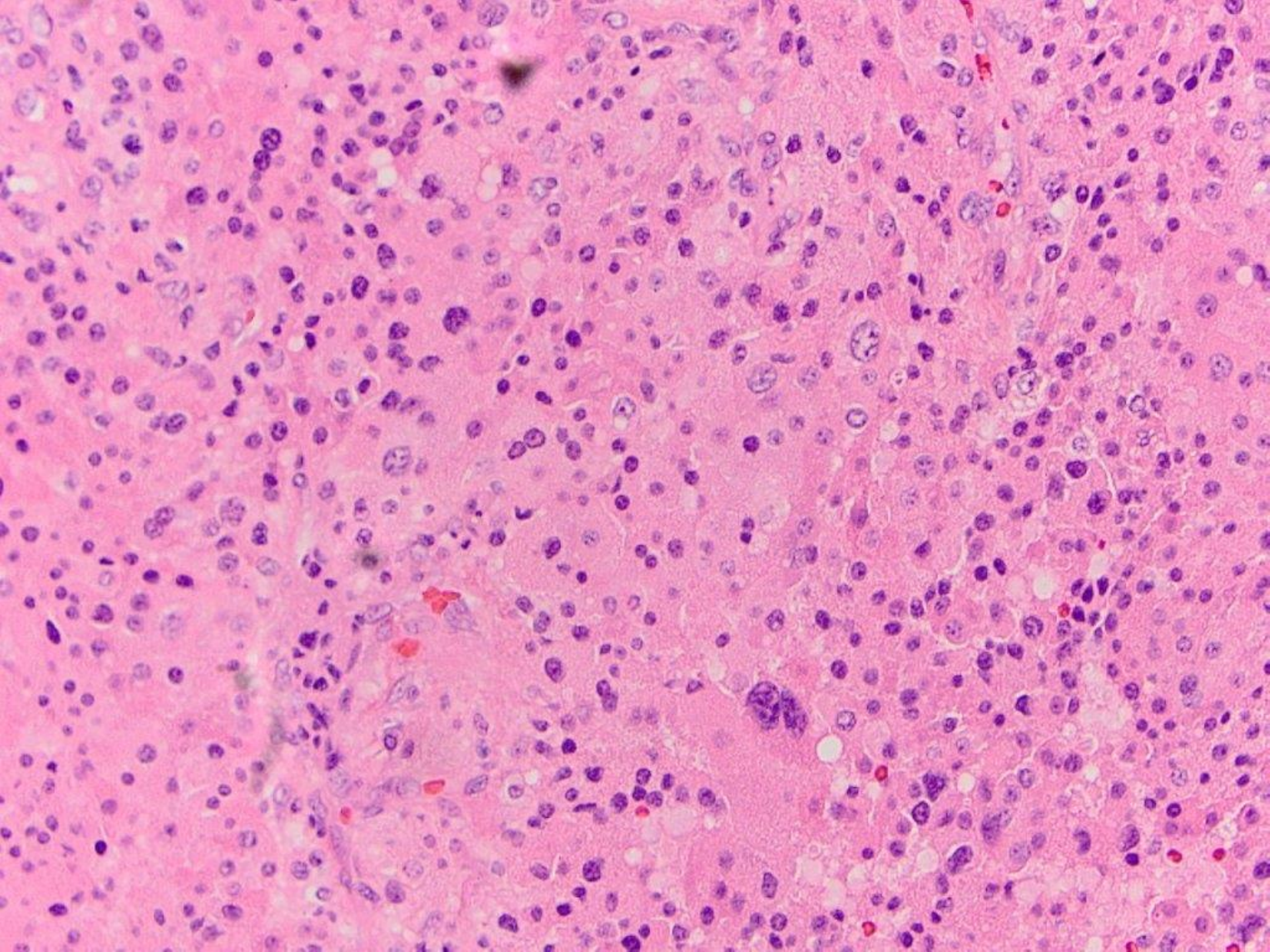


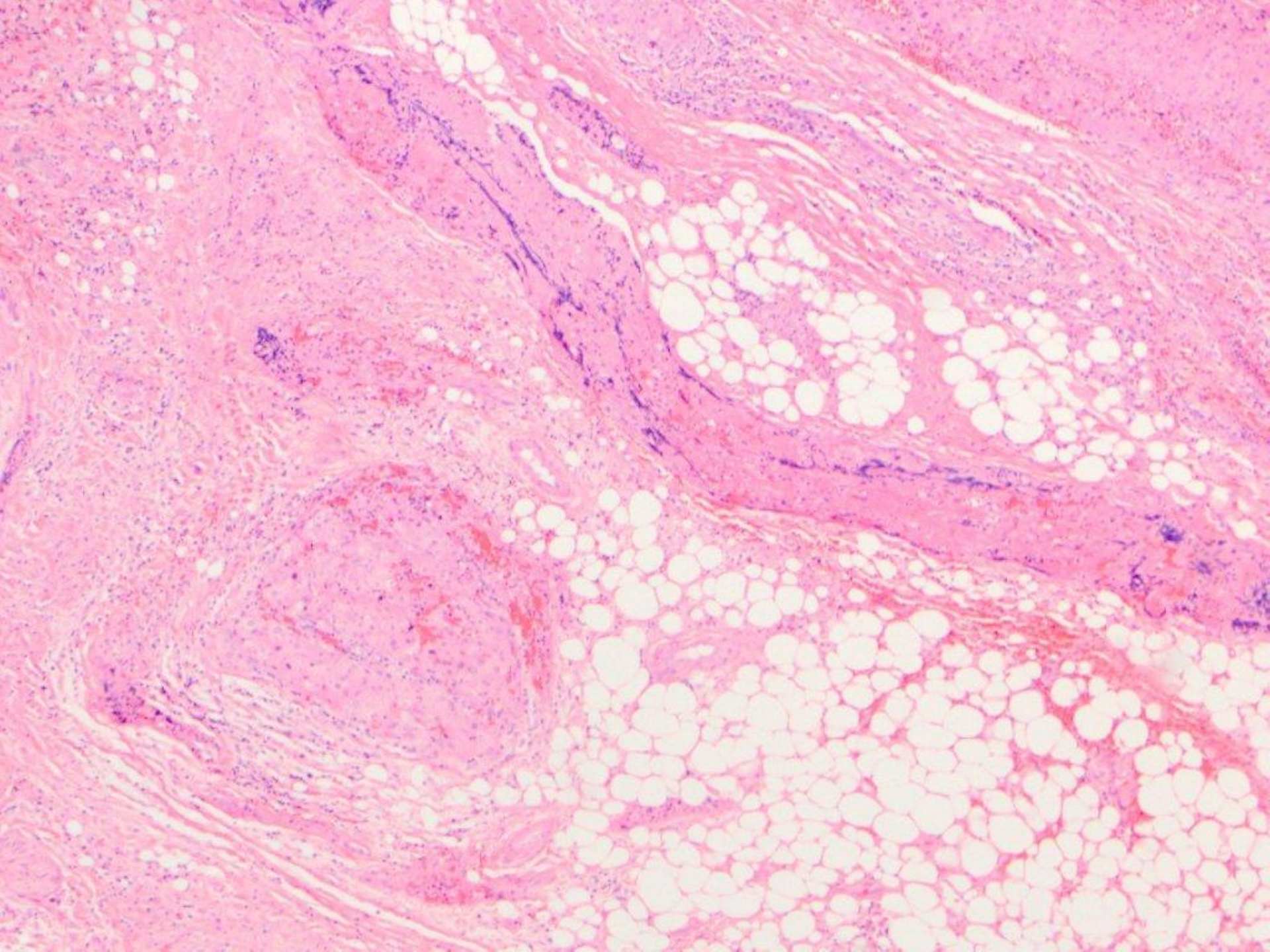
oncocytoma arising in multifocal oncocytosis

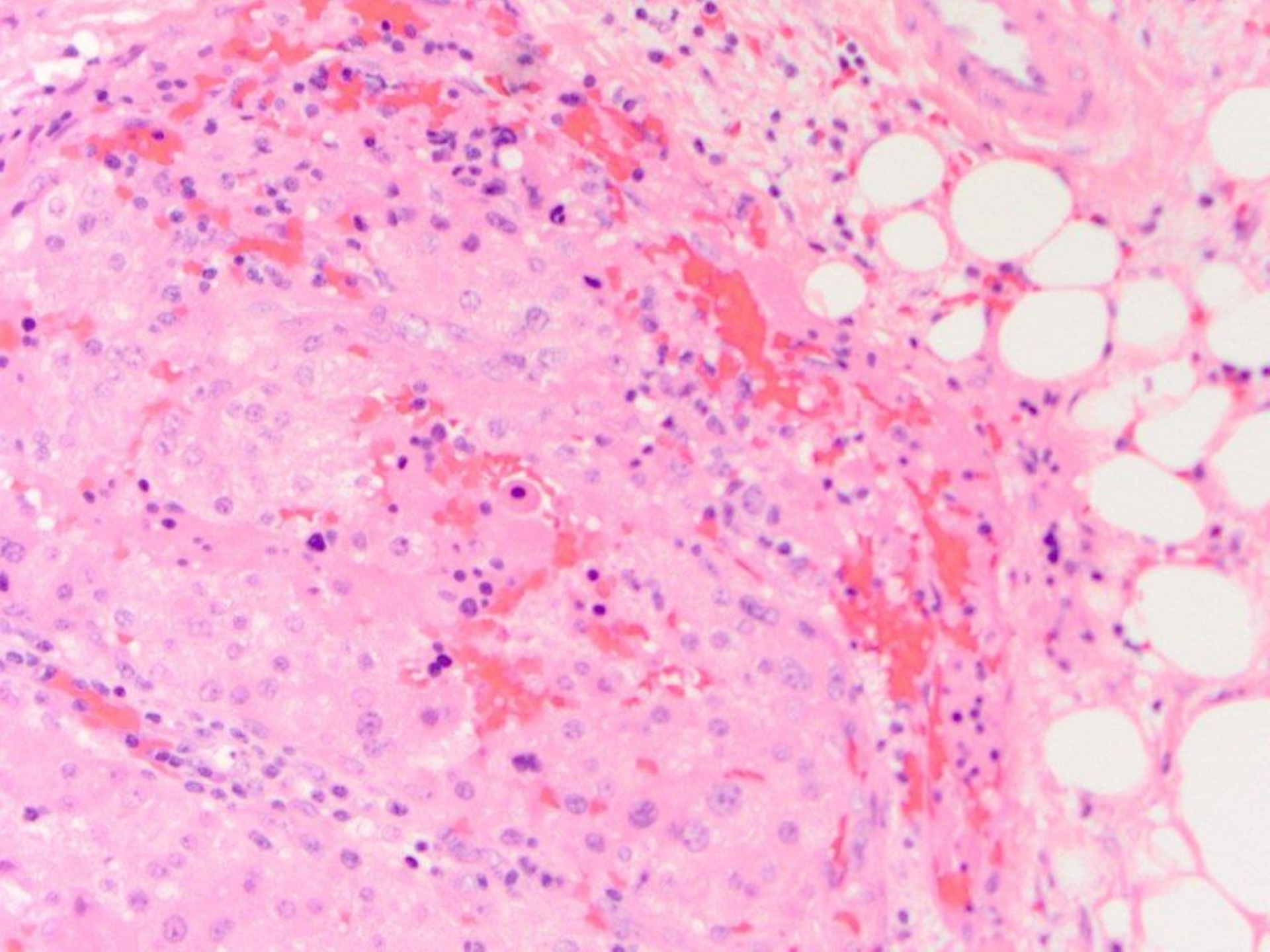


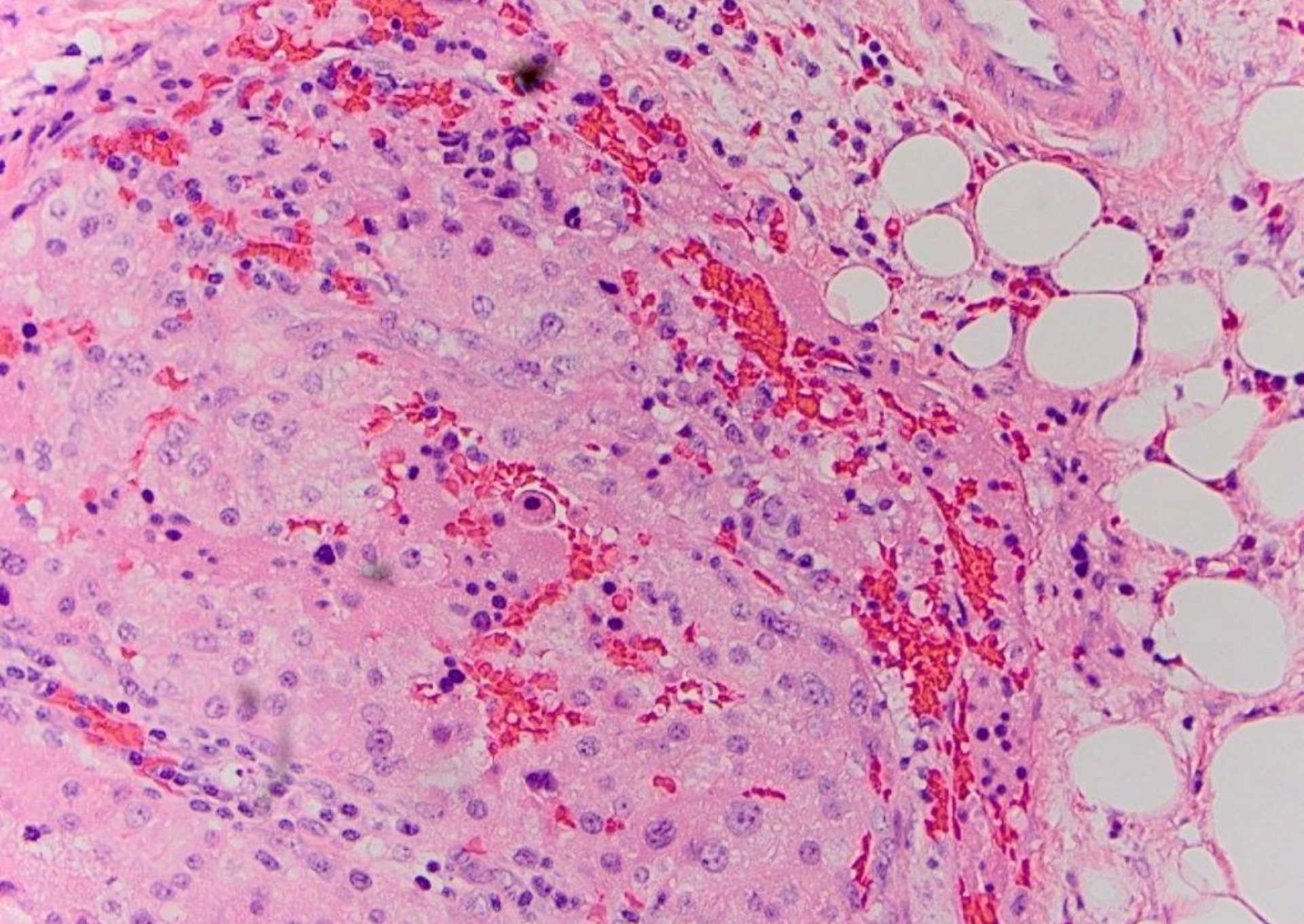




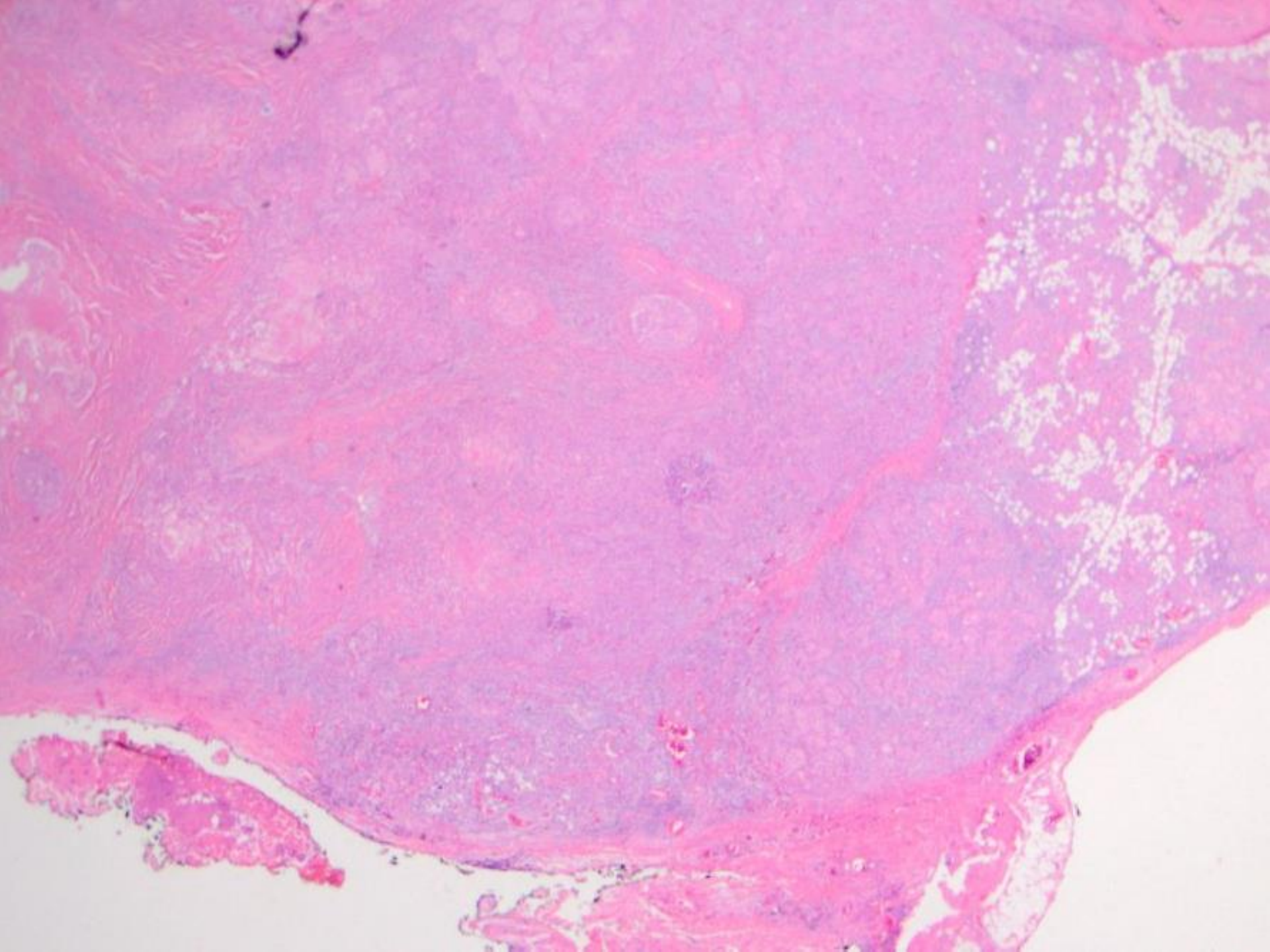


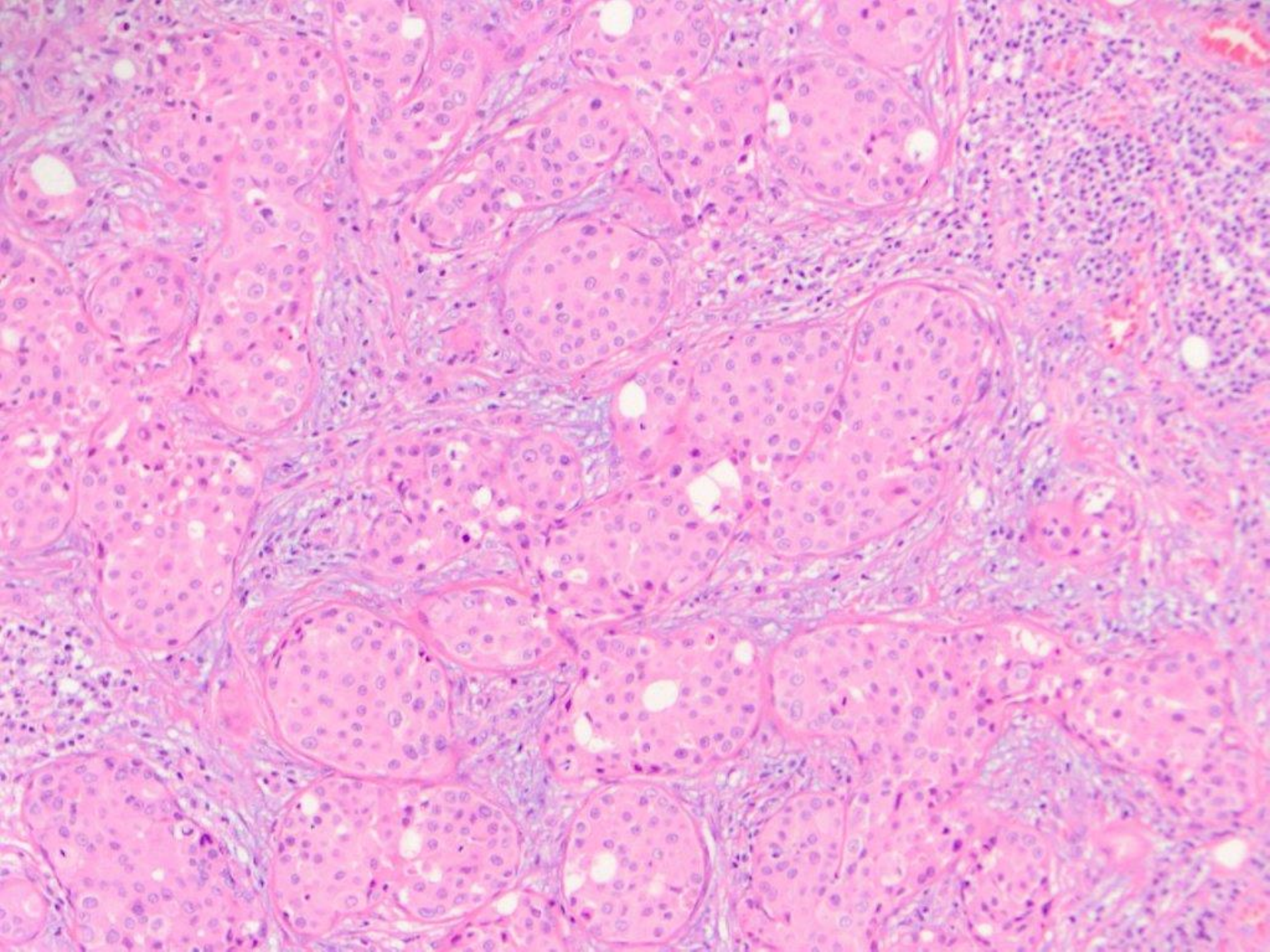


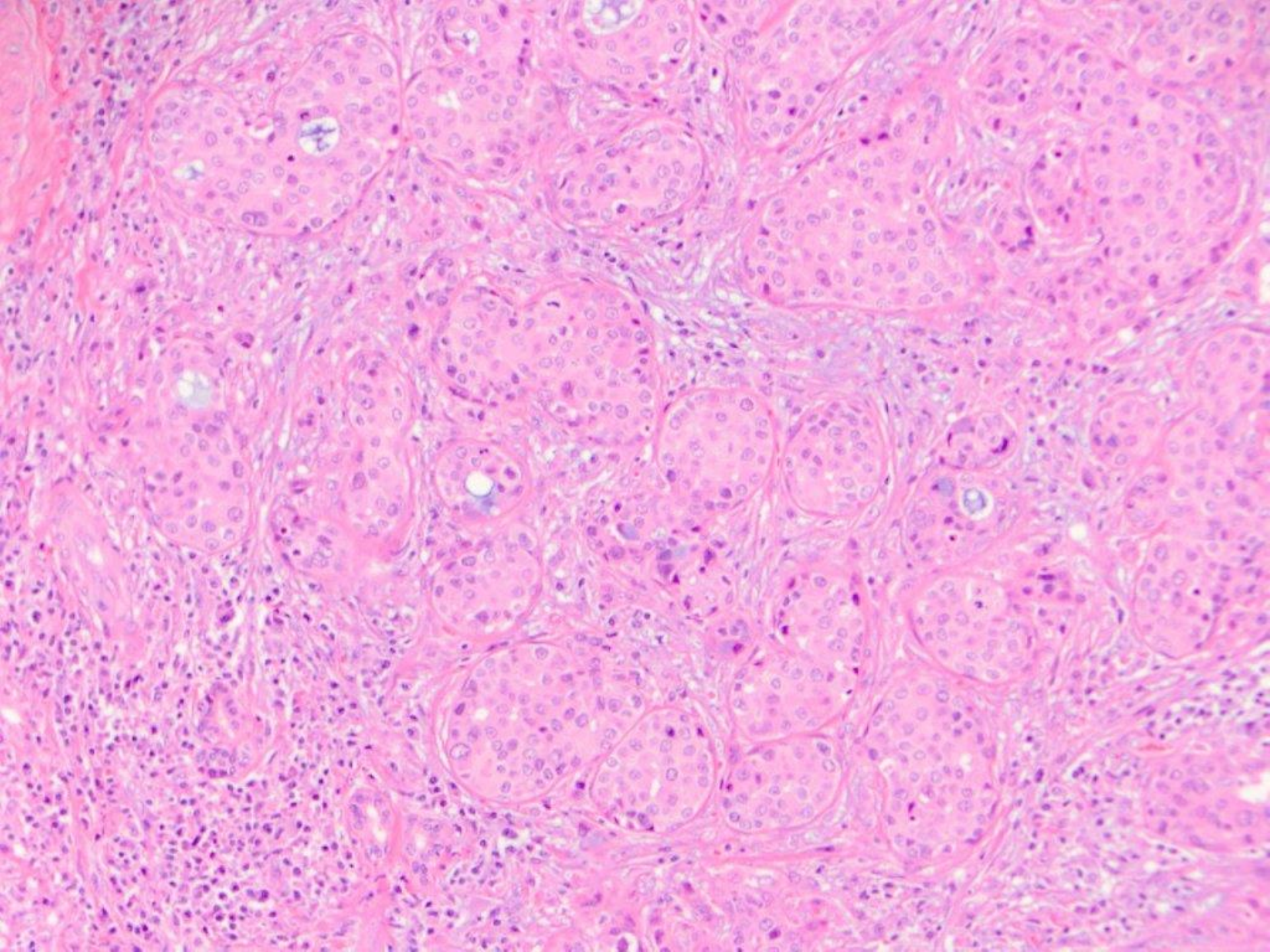


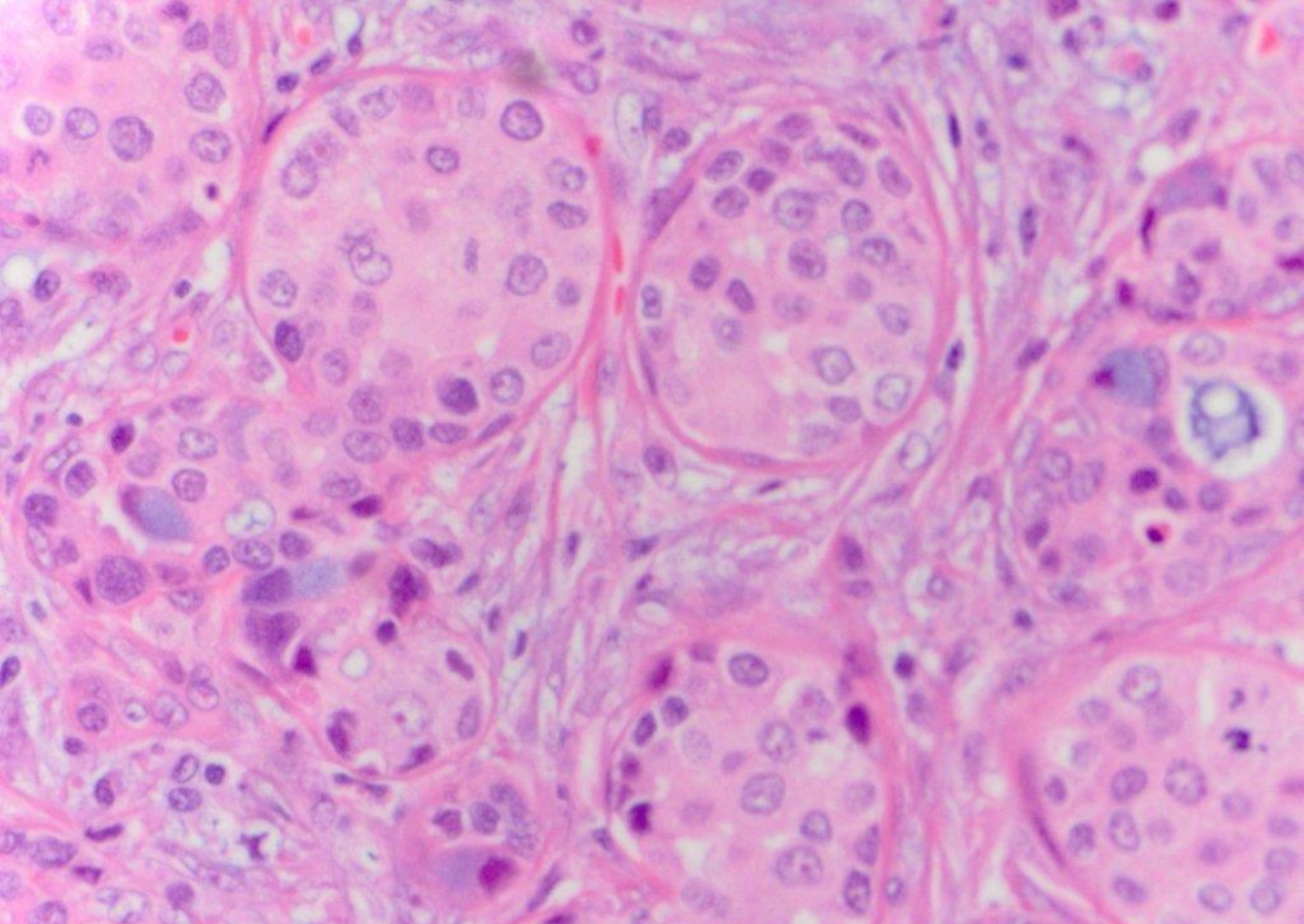


oncocytic carcinoma

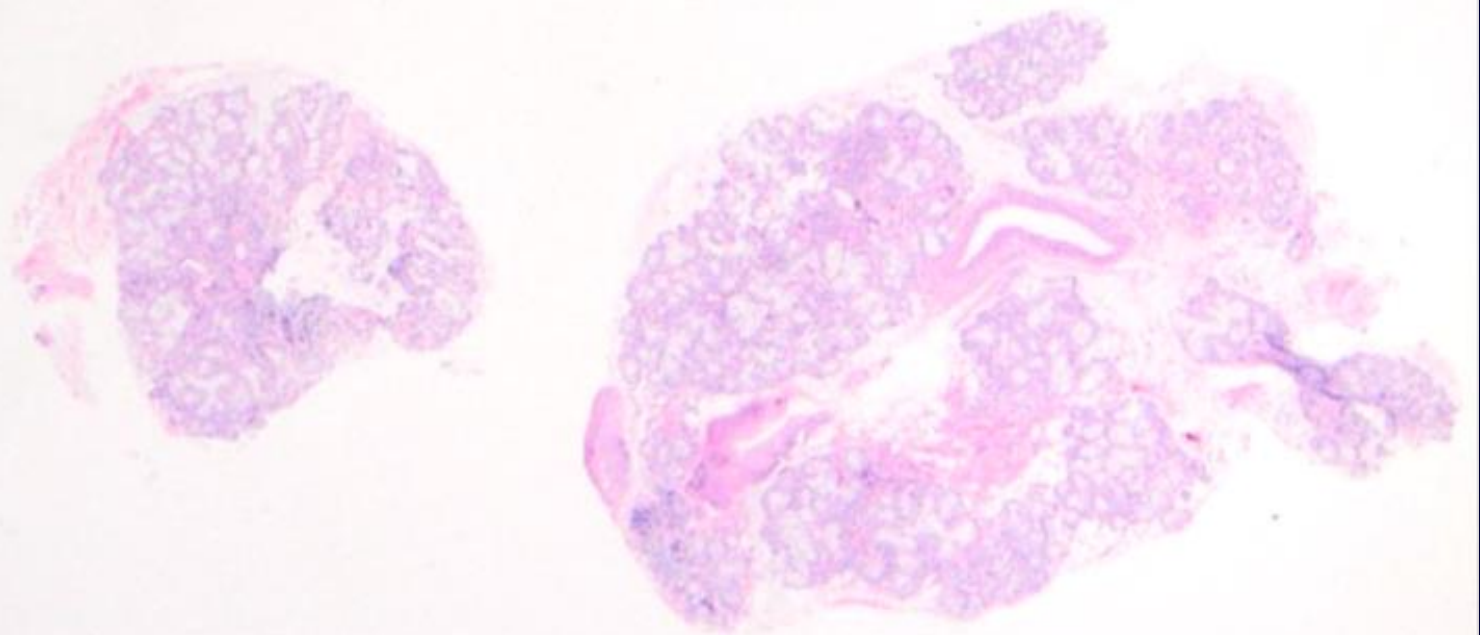
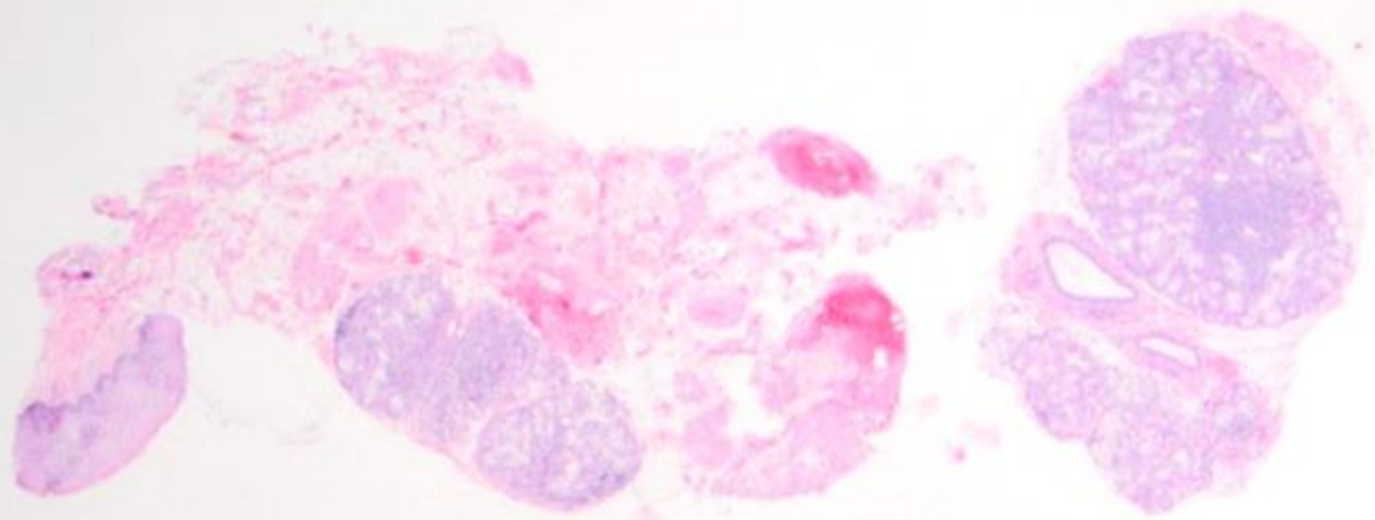


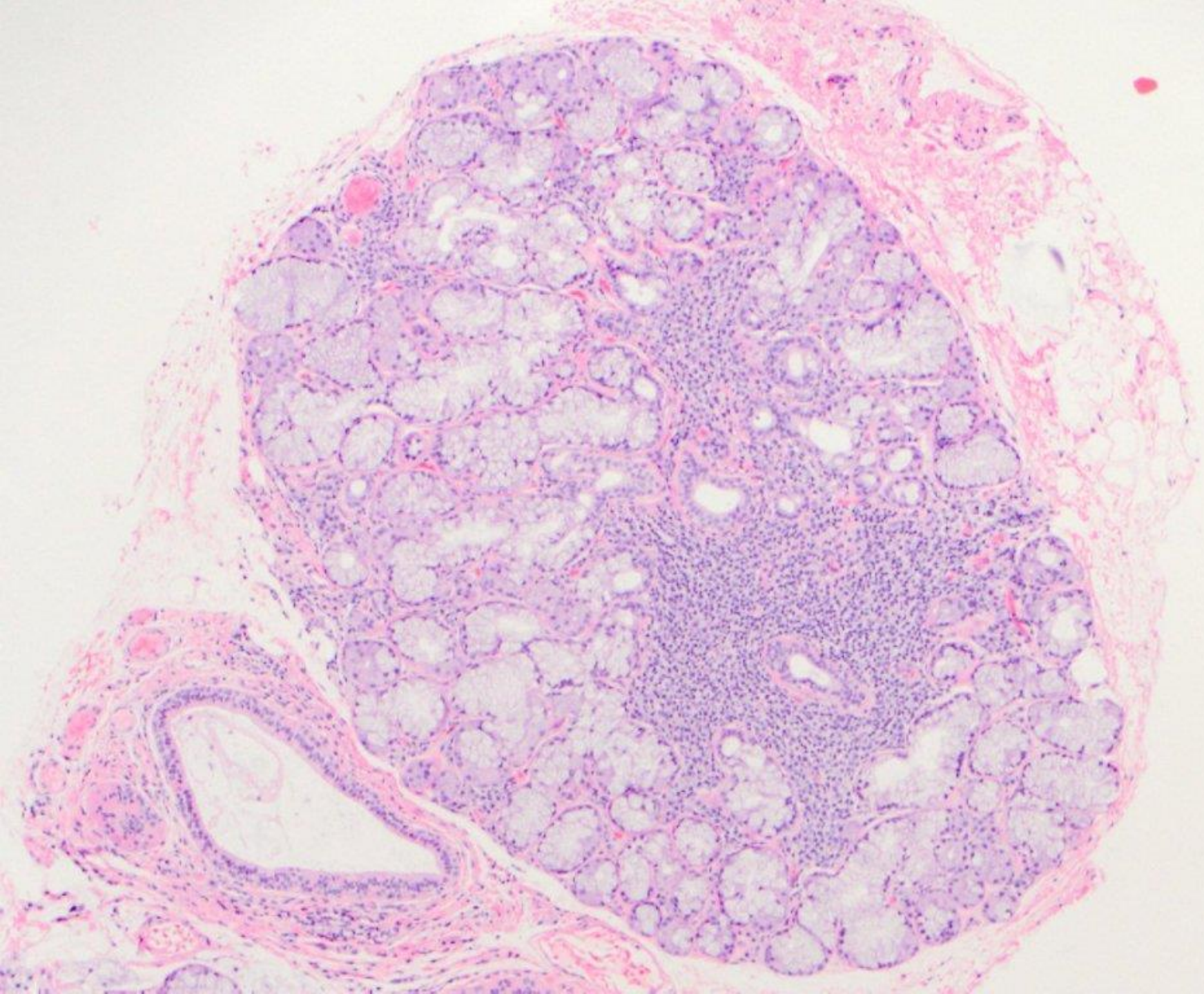


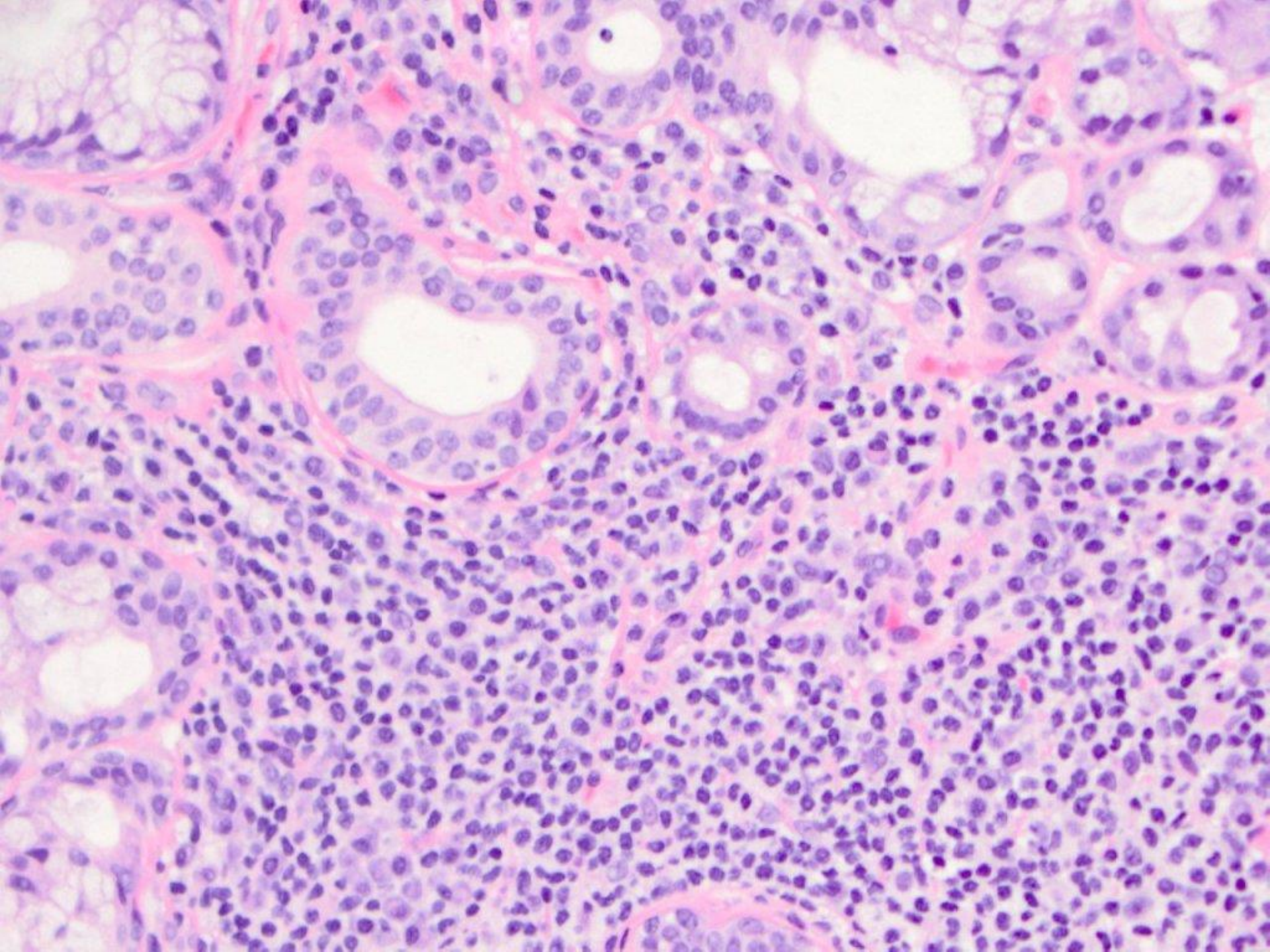


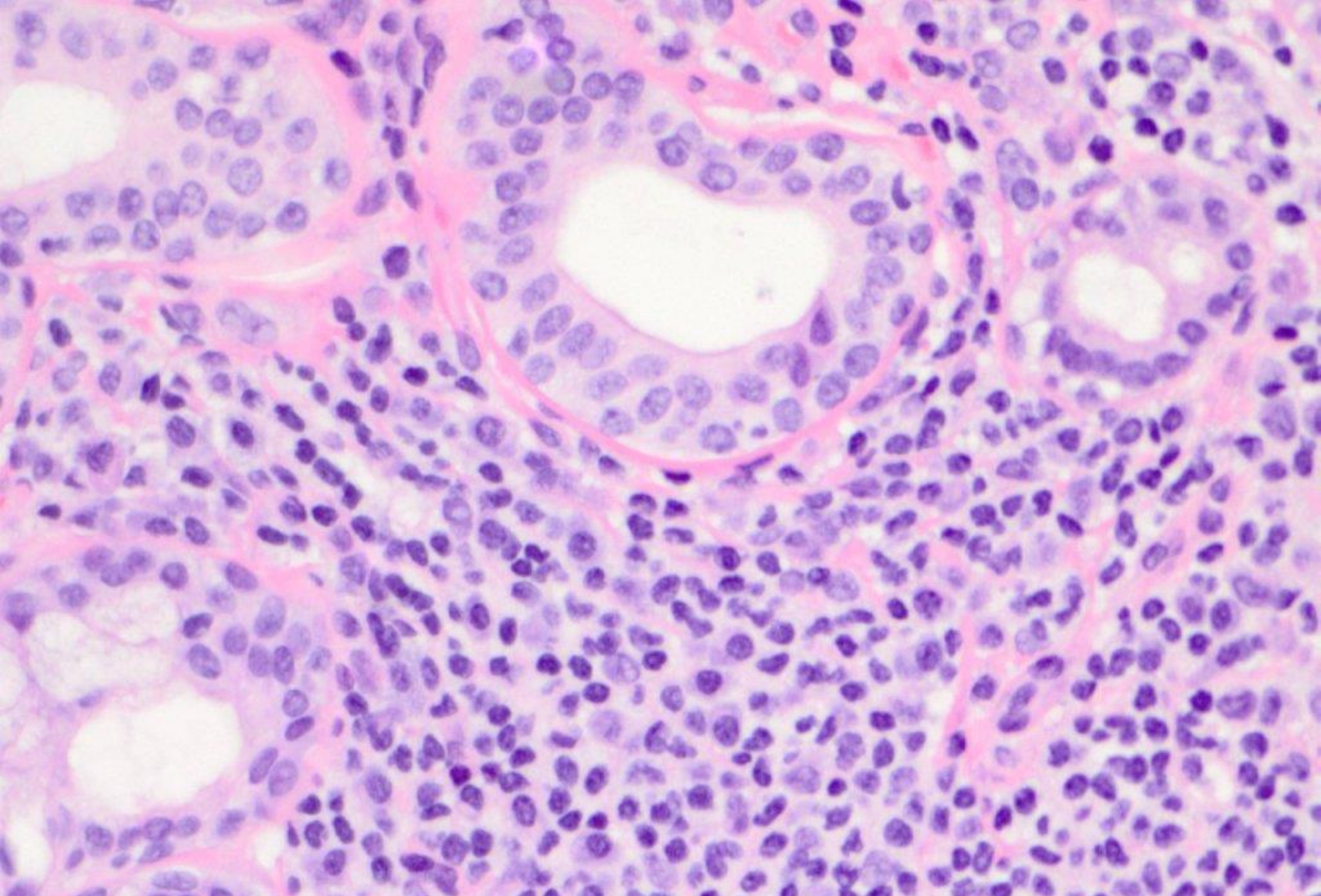


mucoepidermoid carcinoma; high grade

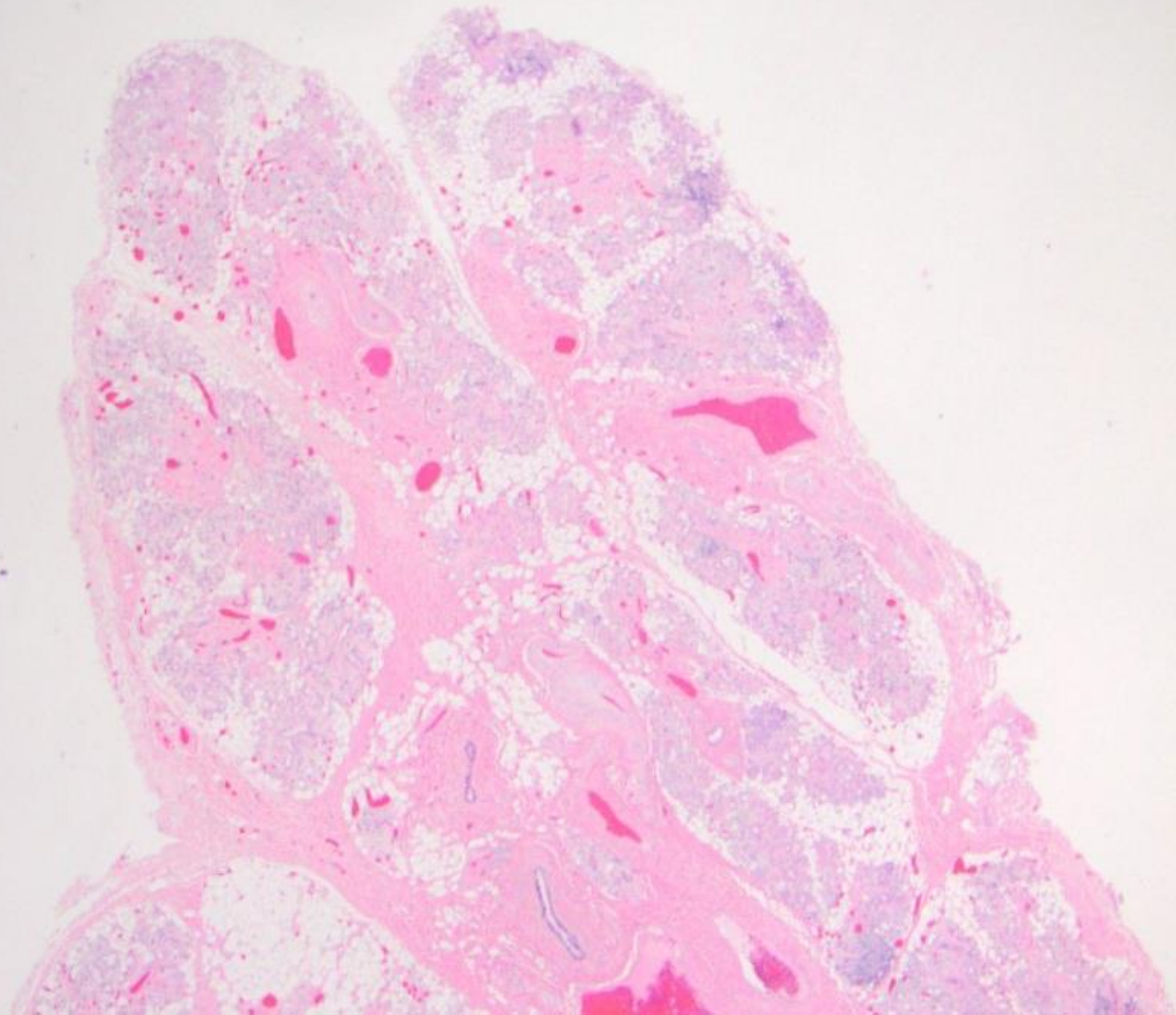


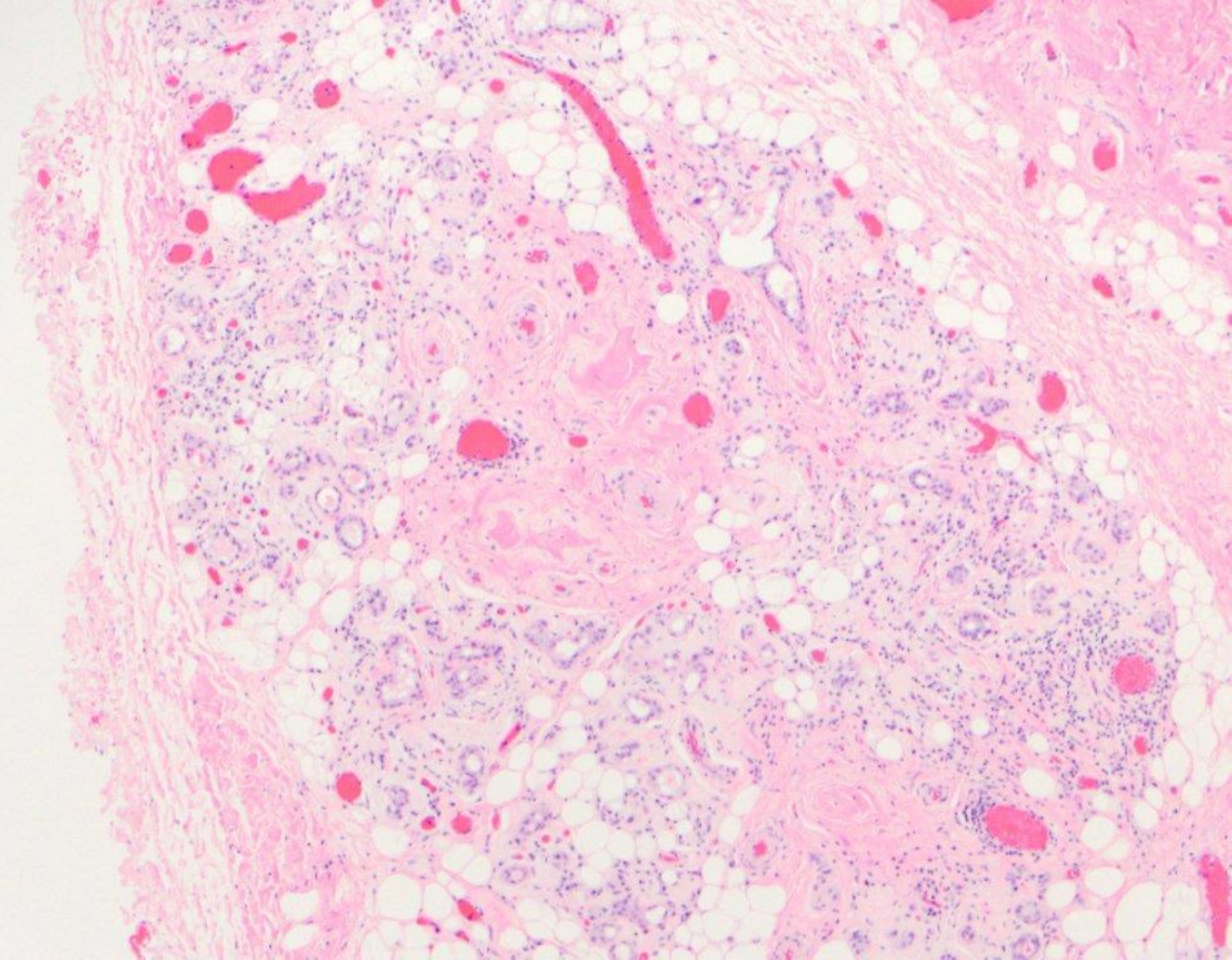


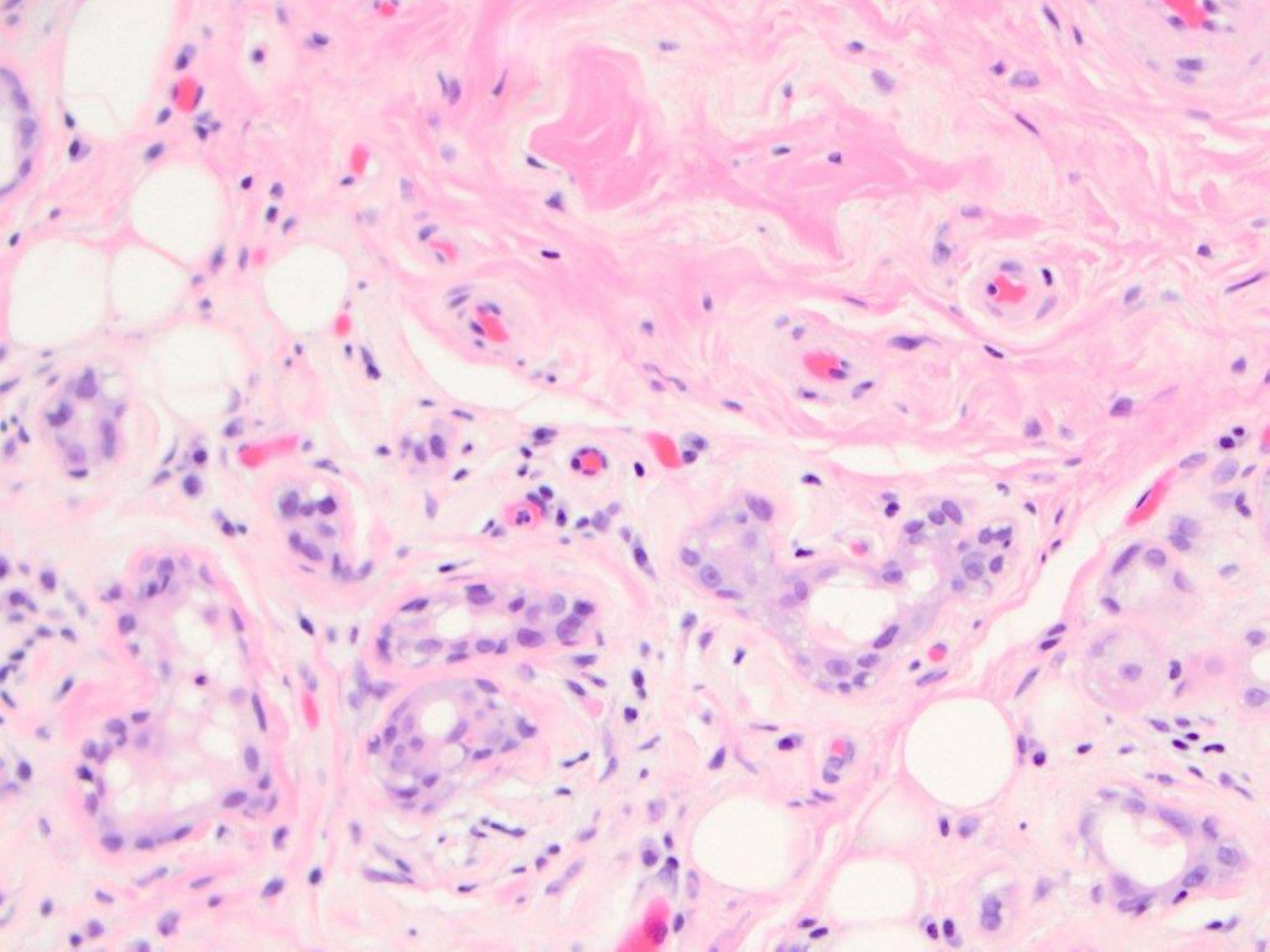


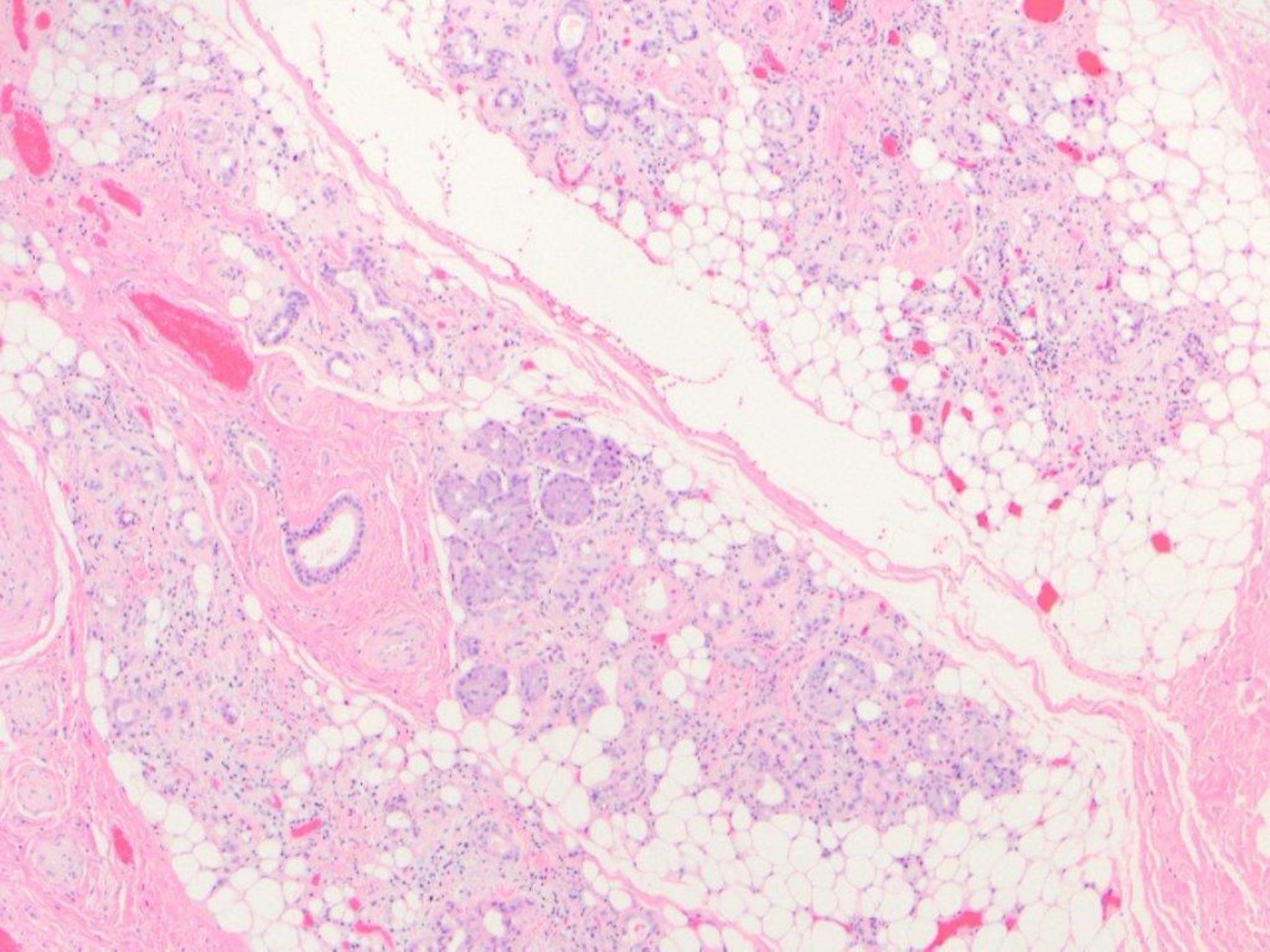


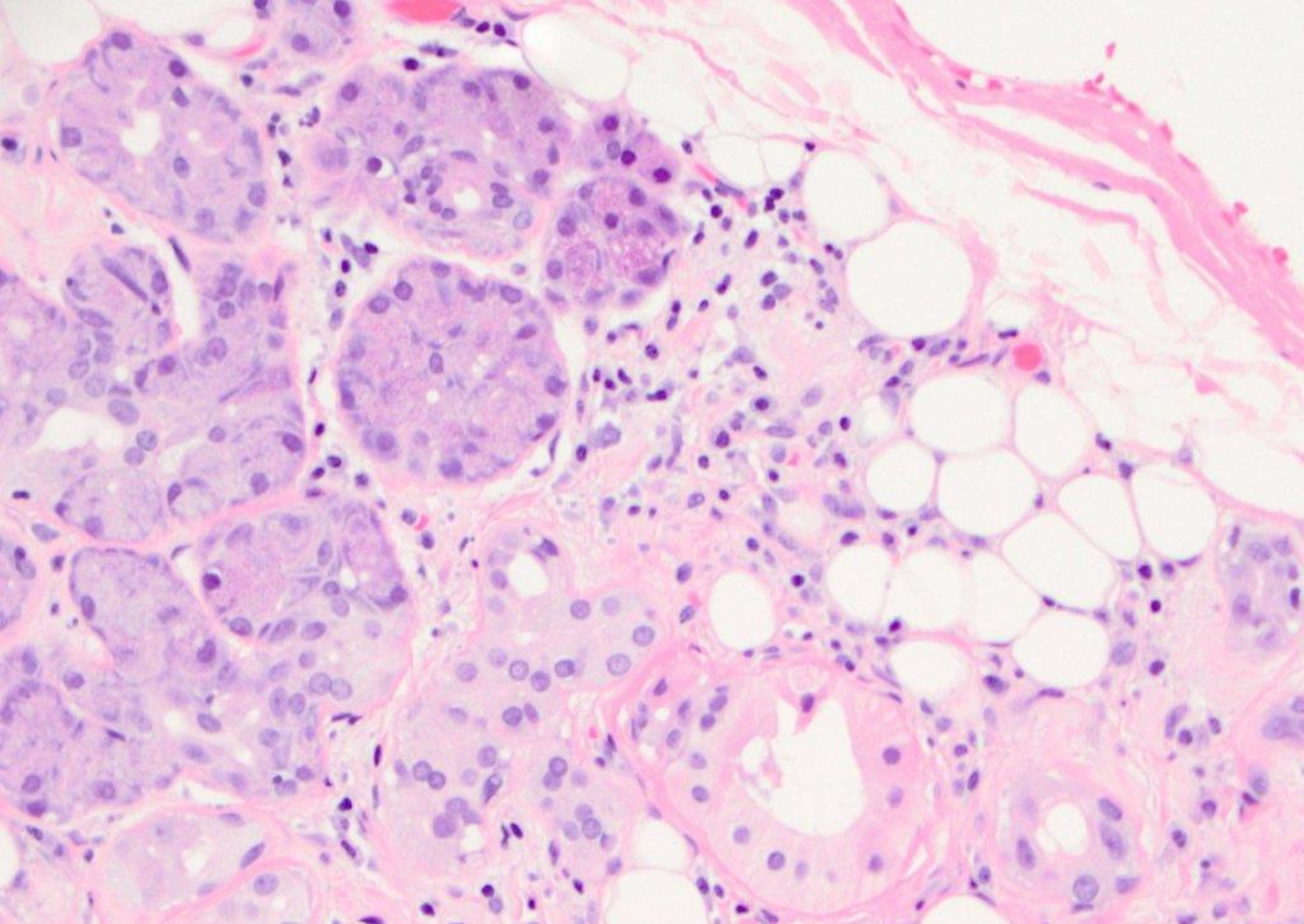
labial salivary gland biopsy, 5-6 lobules, with periductal lymphocytic infiltrate
[histopathologic findings consistent with Sjogren's Syndrome]











radiation-induced salivary gland changes